

World's Largest Distributed Special Ops Magazine

# Special Operations Technology

Annual SOF  
Mobility Review

Ranger  
Warrior

Colonel  
Richard D.  
Clarke

Commander  
75th Ranger Regiment

[www.SOTECH-kmi.com](http://www.SOTECH-kmi.com)

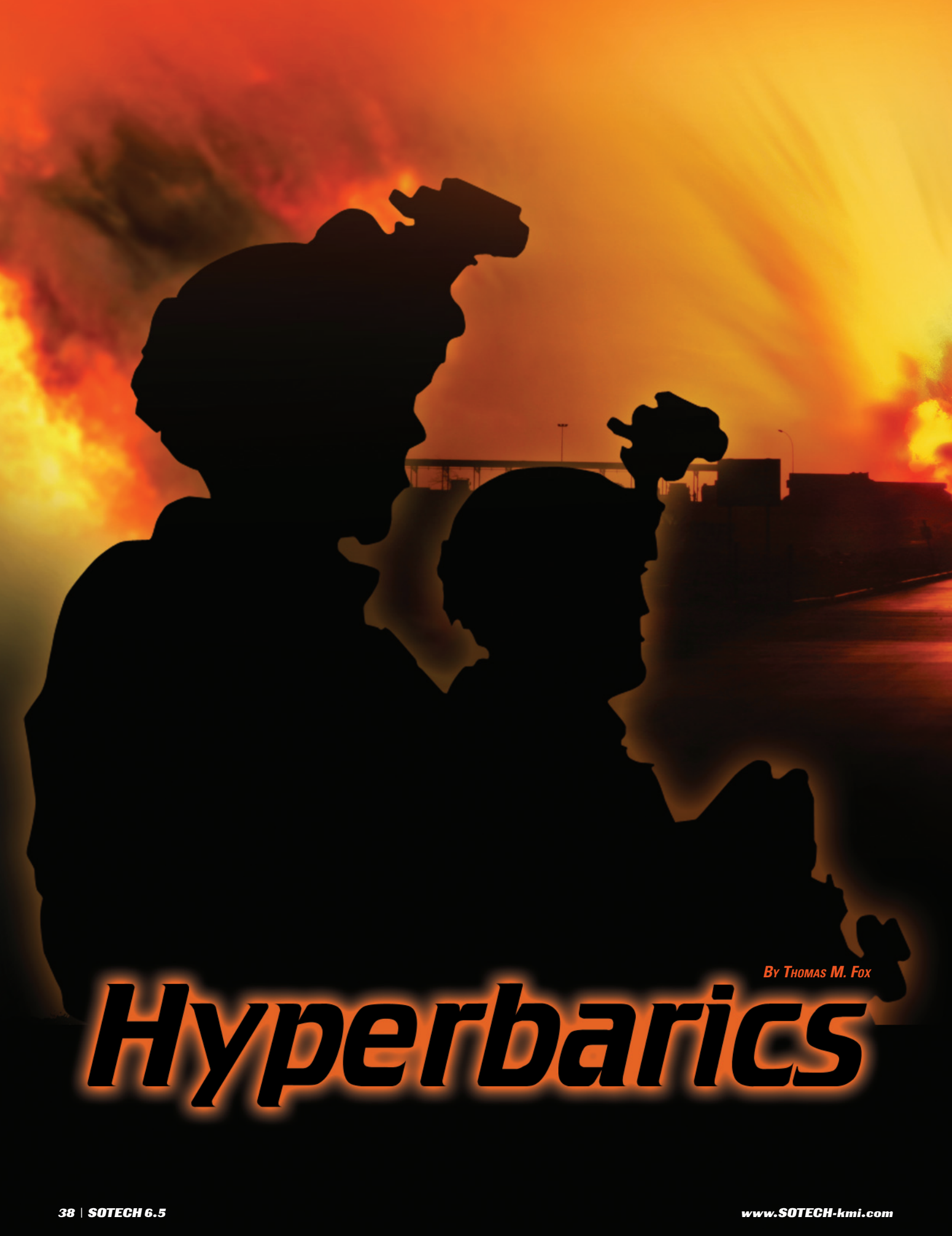**SOTECH**

June/July  
2008

Volume 6, Issue 5

PSRST STD  
U.S. POSTAGE  
PAID  
ROCKVILLE, MD  
PERMIT # 2669

Airborne Armament ★ Civil Affairs ★ Hyperbarics ★ Teak Torch ★ SOFSA



By THOMAS M. FOX

# *Hyperbarics*



***TREATMENT FOR DIVERS MAY BE THE KEY TO UNLOCK THE SECRET TO ADDRESSING THE WAR'S SIGNATURE WOUNDS. HYPERBARIC OXYGEN THERAPY IS IDENTIFIED BY THE OFFICE OF THE SURGEON GENERAL OF THE U.S. ARMY AS DEFINITIVE TREATMENT OF NEUROLOGICAL ABNORMALITIES IN THE BLAST CASUALTY.***

When you mention the term bends to a physician, very few will not be able to answer back that the definitive treatment for this condition is hyperbaric oxygen. Its use in this condition is considered definitive. The bends is slang for a condition known as decompression sickness. This condition occurs when divers are exposed to increased pressure without taking special precautions to prevent bubbles from occurring when leaving pressure.



Smoke and dust rises after an IED explodes in front of a TF 1-27 Inf. convoy. The IED detonated onto the convoy after soldiers were heading back to FOB McHenry following humanitarian missions. No one was injured in the explosion. (Sgt. Sean Kimmons)

Treated with hyperbaric oxygen, the adverse consequences of these bubbles are avoided and the long-term effects of the injuries caused by them are prevented. Untreated, the injury caused by these bubbles may leave the individual with a lifelong disability, whose presentation is dictated by the final resting place of the bubbles.

Today, it is hard to not be aware of the term “the signature wound of the war on terror”. This label has been tossed around like some hard-to-find designer fashion by the press and physicians seeking to explain a set of symptoms exhibited by an overwhelming number of soldiers and veterans who have been exposed to combat in Iraq and Afghanistan. One of the hallmarks of this condition is the absence of obvious external injury. Labeled as shell shock in World War I, this condition was classified as having lack of moral fiber. Today, this injury can be classified as either mild traumatic brain injury or post traumatic stress disorder. A lot of the time, in speaking with professionals, these two terms end up being used interchangeably as the set of symptoms they are attempting to describe are the same.

The truth is, those attempting to explain the signature wound are no closer to understanding this injury than they were 90 years ago. This label used today is different as it has been in each of the wars following the war to end all wars. Yet through these 90

years, the symptoms have remained surprisingly consistent. Since this injury was first observed in World War I, attempts to explain it and address it have subjected U.S. veterans, soldiers and Marines to interventions and questionable scientific trials that have failed to address the mechanism of injury for these wounds and preserve quality of life for those affected. Among the procedures that veterans with this signature wound in the past have been subjected to you will find electroshock therapy, convulsive therapies induced by insulin, lobotomies and great number of drug interventions among which have been LSD and Ecstasy. (Interesting to note a recent article linked the use of “club drugs” to the very conditions for which they were being used to mitigate.)

In the last 90 years, military medicine has advanced quite significantly. Military physicians are performing exceptionally in the theatre. Lives are being saved that would have surely died of injuries in previous conflicts, and despite the exceptional performance of these world-class physicians, the signature wound is occurring in a much higher frequency than has been experienced in recent past conflicts. To date the main focus of this silent wounding in many instances is in the area of mental health, as the concentrated efforts of psychiatrist and psychologists teach the injured to accept and compensate for these injuries, many times using pharmaceu-

ticals to facilitate this objective. Despite the efforts of these professionals the suicide rate of veterans is at an alarming 25-year high.

So what are we looking at? This signature wound is physical wound brought about by the development of emboli as a result of exposure to the overpressure, (pressure impulses and shock waves) that result from the detonation of IEDs or exposure to weapons firing. There are at least four ways in which emboli are formed in the body. First of which can result from the transient overpressurization and overdistention that creates an entry point for air through an alveolovenous fistulae. The second possible explanation for the development of emboli is exceeding the point of critical supersaturation as the detrimental effects of blast overpressure are tied to the magnitude of the pressure and the duration of the exposure. This is in much the same manner that emboli are formed in decompression sickness. The third possible explanation for the formation of emboli in the body of the blast casualty has to do aerodynamically with the area immediately preceding the hypersonic pressure impulses impacting the head and neck of the blast casualty. The formation of bubbles in this area of compressible turbulence is well documented and capable of being photographed. Finally, the fourth possible explanation of emboli formation may be related to nanocavitation. This event has been studied and documented by biophysicists.


The symptoms of this signature wound are brought about by the invisible subtle wounding of the primary blast injury as emboli are formed as a result of overpressure followed by an unchecked decompression that is well described by those subjected to these blast effects. This injury can be seen to worsen with evacuations that involve excursions from ambient pressure. The injuries are also more pronounced in the individual that has had more strenuous physical activity following exposure to blast overpressure. Additionally it can be suspected that the injury is more pronounced in the casualty that is dehydrated.

Physicians can not diagnose what they are not trained to recognize. The time is now to set aside misconceptions and preconceptions of physicians that were well founded and based on charlatans of past generations? It is time to train today's physicians on a treatment option that can address the patients under their care and avoid long term neurological disabilities and costs. There are over 100 years of studies and investigations supporting the use of hyperbarics in treating emboli. Current investigations into this treatment modality, suggest that hyperbaric oxygen conveys neuroprotection for a period of several days following exposure.

sure. The emboli created during the exposure to extreme pressure changes are definitively treated with hyperbaric oxygen. ★

---

*Thomas Fox is the staff physiologist with Centre Hyperbare de L'Île in Pincourt Qc. His last assignment in the United States Army was as the chief of the Atmospheric Branch of the United States School of Aviation Medicine responsible for investigations, instruction and training of hyper/hypobaric environment. Fox is a graduate of United States Army Command and General Staff School and an aeromedical evacuation pilot*



This is the new hyperbaric chamber that will hold up to 22 patients. [Journal photo by Doug Lindley]

Why does it seem that military physicians go to extremes not to recognize a mechanism of injury that has been identified since 1942? Therapeutic hyperbaric oxygen was identified as definitive in addressing neurological abnormalities in the blast casualty in 1990 in a comprehensive textbook produced by the Office of the United States Army Surgeon General. With military physicians struggling to determine the appropriate approach to an injury created by exposure to extraordinary pressure, isn't it time to select a definitive therapy to address the emboli created by the overpressure?

The blast casualty presents the military physician with a very complex patient. The blast injuries they sustain are compound. The care of the primary blast injuries (insults created by overpressure) are usually subordinated to the care of secondary or tertiary blast injuries. Primary blast injuries are real, other than the most dramatic (ie., blast lung), which have been cited as the number one of immediate death following exposure to blast overpressure; these injuries are very subtle, usually with no evidence of external injury. They also present as long as 36 hours post exposure to the blast overpres-

*sure with 10 years experience. Since leaving the service in 1994, Fox's work experience has been in a number of positions in which he has performed as the technical director for hospitals as the hyperbaric service provider in the critical care setting.*

For more information, contact *SOTECH* Editor Jeff McKaughan at [jeffm@kmiimagroup.com](mailto:jeffm@kmiimagroup.com) or search our online archives for related stories at [www.SOTECH-kmi.com](http://www.SOTECH-kmi.com).