

Synovial Membrane Scanning in Arthritic Disease

By William S. Maxfield, Thomas E. Weiss, and Stanton E. Shuler

Arthritis is a common disease frequently difficult to diagnose in its early stage. In many cases it is difficult to separate a nonarthritic joint complaint from the early stage of inflammatory arthritis. Synovial membrane scanning is an objective technique that can detect synovitis before it becomes apparent clinically or roentgenographically. The synovial membrane scan can document the pattern of synovitis at a given time and by repeat scans measure the progression of disease or response to therapy. Evaluation of the synovial membrane began with measurement of permeability after intraarticular injection of radiopharmaceuticals. Research in the technique of synovial membrane scanning after i.v. administration of radiopharmaceuticals has been under way for 7 yr. The ^{131}I human serum albumin and ^{131}I iodipamide initially employed as tracers were used as research techniques since the radiation dose was moderately high and the scanning time was long. The use of short half-life tracers, such as $^{99\text{m}}\text{Tc}$ tagged albumin and pertechnetate ($^{99\text{m}}\text{TcO}_4$), with a stationary imaging device, make synovial membrane scanning a practical clinical procedure. The i.v. dose of $^{99\text{m}}\text{TcO}_4$ has varied from 5 to 15 mCi. The local-

ization of the tracers after i.v. injection in areas of synovitis is nonspecific, but the pattern of joint involvement may aid in the differential diagnosis of arthritis. Synovial membrane scanning is of particular value in the patient with joint pain when other laboratory and clinical studies are borderline and/or normal. A negative synovial membrane scan is further confirmation of the lack of synovitis, suggesting that the pain is nonarthritic in origin. Conversely, a positive scan has a high degree of correlation with eventual confirmation of synovitis due to an arthritic condition by other tests weeks to months later. Comparison to routine roentgenography of the joints of the extremities indicates that the synovial membrane scan is 30% more accurate than X ray in detecting synovitis. In some patients the synovial membrane scan exceeds clinical evaluation, particularly in the knee joint. The synovial membrane scan provides another objective and sensitive method for following the course of a patient's arthritis, either in assessing response to treatment or progression of disease. Documentation of the usefulness of synovial membrane scanning by several authors indicates that this technique should be a routine procedure in most nuclear medicine laboratories.

ARTHRITIS IS A COMMON DISEASE frequently difficult to diagnose in its early stage. The difficulty in many cases is the problem of separation of nonarthritic complaint from the early state of inflammatory arthritis. Not only is it difficult to diagnose early arthritis unequivocally, but it may be difficult to determine the type of arthritis. Review of the diagnostic criteria for arthritic conditions indicates that reliance has been placed upon history, physical examination, laboratory, and roentgenographic studies. The availability of synovial membrane scanning provides another evaluation modality

From the Ochsner Foundation Hospital and Charity Hospital, New Orleans, La.

Supported in part by a grant from The Arthritis Foundation, Louisiana chapter.

William S. Maxfield, M.D.: Professor and Chairman, Department of Radiology, Louisiana State University Medical School, New Orleans, La. Thomas E. Weiss, M.D.: Rheumatology Section, Department of Internal Medicine, Ochsner Clinic, New Orleans, La. Stanton E. Shuler, M.D.: Department of Pediatrics and Radioisotope Laboratory, Ochsner Clinic, New Orleans, La.

that can objectively document synovitis at an early stage. Though the localization of the i.v. administered tracers is nonspecific, the pattern of joint involvement in the extremities may aid in the differential diagnosis. The synovial membrane scan also provides an objective technique for measurement of progression of disease or response to therapy.

HISTORY

Evaluation of the synovial membrane with radiopharmaceuticals was initiated in the 1950's by Ahlström,¹ Harris,² and Rodnan.³ The tracers used were Iodinated human serum albumin (¹³¹IHSA), ¹³¹I-tagged globulin, and radioactive sodium. The technique of measurement of the clearance of intra-articularly injected radiopharmaceuticals has recently been pursued by St. Onge⁴ and Dick^{5,6} employing ¹³³Xenon. These studies indicated that there is a change in the permeability of the synovial membrane in rheumatoid arthritis. Roucayrol et al. have compared the accuracy of scanning, after intraarticular injection of radiopharmaceuticals into the knee, to roentgenographic evaluation after contrast media injection.⁷ Limentani et al employed external counting to detect localization of i.v. administered ¹³¹IHSA.⁸

The technique of scanning the synovial membrane of the extremities after i.v. injection was initiated by Weiss and Maxfield.⁹⁻¹² The initial studies were with ¹³¹IHSA (Fig. 1). This tracer was effective in demonstrating synovitis (Fig. 2), but the radiation dose from the radiopharmaceutical was moderately high and the photon yield was low. The low photon yield made the use of stationary imaging devices impractical and gave a scanning time of approximately 4 hr for a study of the hands, wrists, and knees with a 3-inch crystal rectilinear scanner. Introduction of ¹³¹Iodipamide with its shorter biological half time reduced the radiation dose.¹³ ¹³¹Iodipamide permitted the use of a larger quantity of ¹³¹I, thus reducing the rectilinear scanning time to 2-3 hr. It was demonstrated that a stationary imaging device could be employed with this tracer, but the detail, particularly of the hands, was poor. The lack of detail was due to the low photon yield and inefficiency of the Anger camera unit (Nuclear-Chicago Pho-gamma Mk III) at ¹³¹I energy. ¹³¹IHSA and ¹³¹Iodipamide synovial membrane scanning, therefore, proved to be a research rather than a practical clinical procedure due to the long scanning time. Development of the use of ^{99m}Tc-tagged albumin as a synovial membrane scanning agent provided a radiopharmaceutical with a low radiation dose and a high photon yield.¹⁴ Determination that ^{99m}Tc pertechnetate (^{99m}TcO₄) could also be used for synovial membrane scanning provided a readily available, short half-life tracer.^{13,15-20} Application of stationary imaging devices such as the Anger camera with short half-life radiopharmaceuticals such as ^{99m}TcO₄ reduced the scanning time to 1 hr for evaluation of all of the joints of the extremities (Fig. 3). The ability to study all the peripheral joints in a reasonable time made synovial membrane scanning a technically practical clinical procedure.

RADIOPHARMACEUTICALS

¹³¹IHSA was the first i.v. tracer employed for synovial membrane scanning. ^{99m}Tc albumin and ¹³¹Iodipamide have also been employed. The radiopharma-


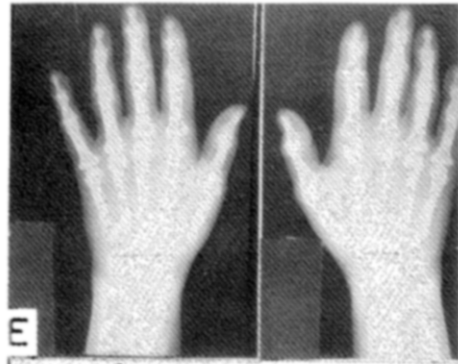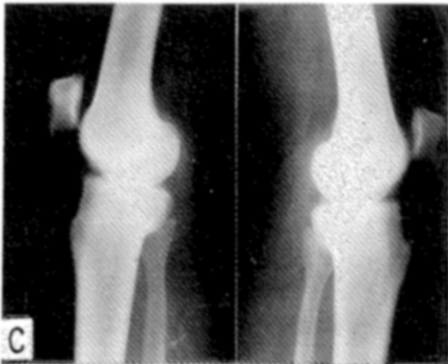


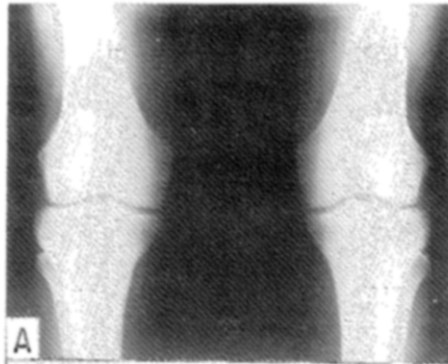


Fig. 1. Normal synovial membrane scans 6 hr after i.v. administration of ^{113}In -HSA. Roentgenograms of knees (A) show area scanned from anterior aspect (B). Lateral roentgenograms (C) show area scanned from medial aspect of knee (D). Roentgenograms of hands (E) show area scanned (F). Note that only normal vascularity is shown. Synovial membrane areas are not identified.

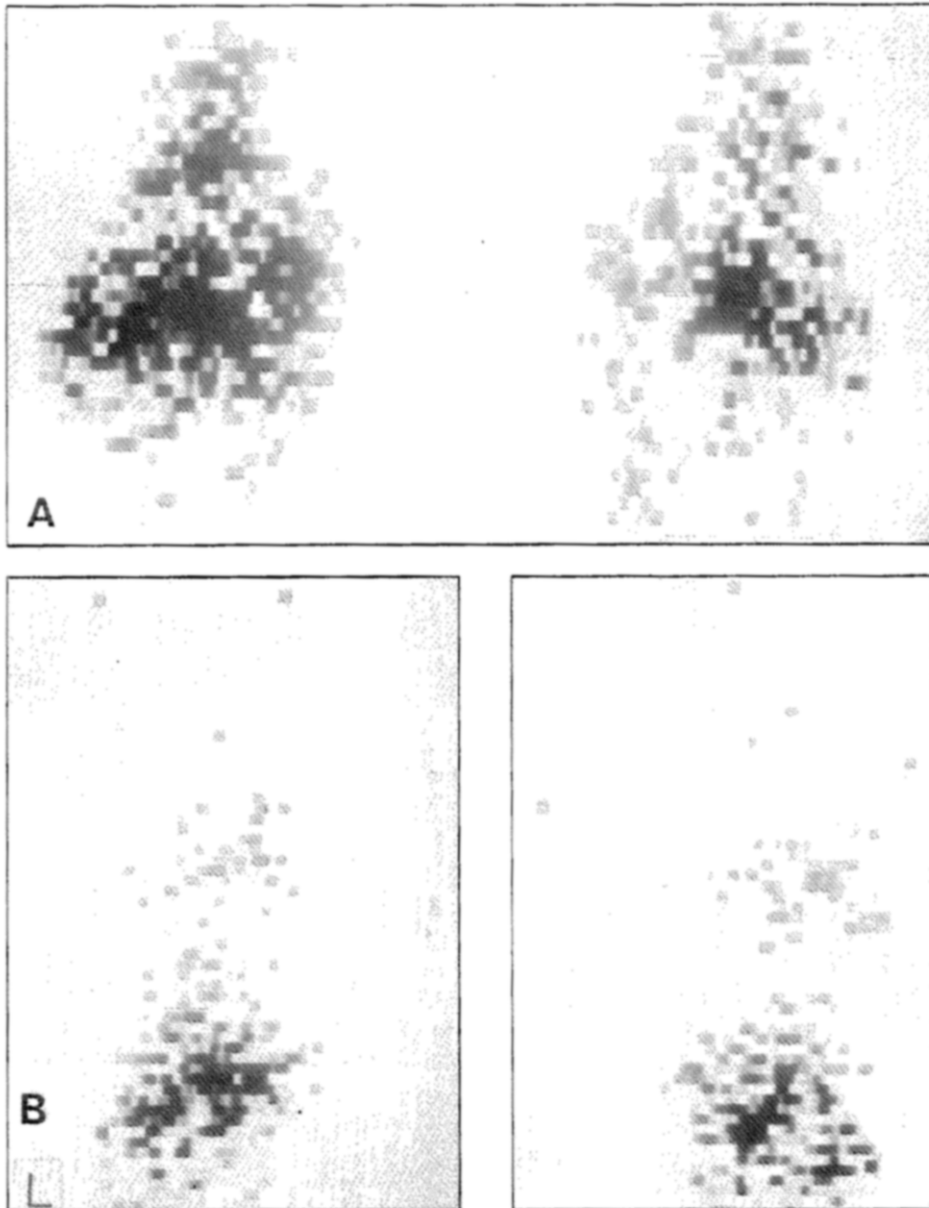


Fig. 2. ^{131}I ISHA scans of patient with typical rheumatoid arthritis confirmed by laboratory studies and biopsy of synovial membrane of left knee. (A) Anterior scan of knees showing greater degree of localization on right than on left. This pattern of localization correlated with clinical symptomatology. Roentgenograms did not detect difference between knees. (B) Scans from dorsal aspect showing positive localization in both wrists and second and third metacarpophalangeal (MCP) joints of left hand and predominately in third, fourth, and fifth MCP joints of right hand.

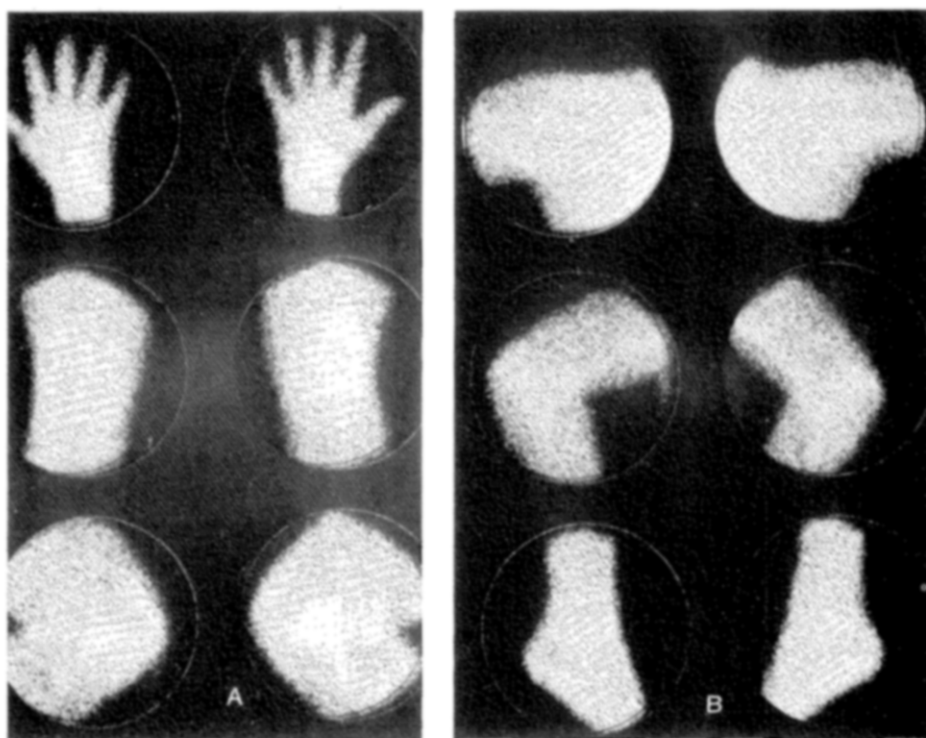


Fig. 3. ^{99m}Tc pertechnetate synovial membrane camera scans of patient with no history of joint disease. Faint localization in synovial membrane areas is normal with $^{99m}\text{TcO}_4$. Localization is in contrast to no localization in normal synovial membrane area with tagged albumin tracers or with ^{131}I iodipamide. (A) Dorsal view of hands, anterior knees, and lateral knees. (B) Anterior shoulders, anterior elbows, and lateral ankles.

ceutical most widely used at the present time is ^{99m}Tc pertechnetate ($^{99m}\text{TcO}_4$). The $^{99m}\text{TcO}_4$ has a disadvantage in comparison to the other radiopharmaceuticals in that it does show a faint localization in the normal synovial membrane (Fig. 3-5). It is therefore necessary to learn to interpret the normal pattern for the tracer employed before attempting to evaluate the abnormal. The advantages of ready availability of $^{99m}\text{TcO}_4$ and avoidance of administration of a foreign protein outweigh the problems of the faint localization in the normal synovial membrane.

Other radiopharmaceuticals such as ^{113m}In ¹⁶ and ^{99m}Tc DTPA²¹ appeared to have value (Fig. 4). The ideal tracer for synovial membrane scanning has therefore not been unequivocally established. However, the data reported to date indicate that synovial membrane scanning with $^{99m}\text{TcO}_4$ and a stationary imaging device is a useful procedure in the evaluation of patients with known or suspected arthritis.^{13,17,18,22}

The localization of the radiopharmaceuticals currently employed in synovial membrane scanning is nonspecific. Positive localization has been reported in synovitis associated with rheumatoid arthritis, gout, infectious arthritis,

tenonitis, bursitis, osteoarthritis, polyarteritis, lupus erythematosus, psoriasis, and Reiter's disease. The mechanism of localization of the tracer has not been exactly defined. In the normal synovial membrane area, there is a slow accumulation of the radiopharmaceutical as the activity in the vascular space falls (Fig. 5). This pattern of accumulation of $^{99m}\text{TcO}_4$ in the synovial membrane has also been reported by McCarty et al.²⁰ Aspiration of fluid from articular spaces with effusion followed by electrophoresis of the fluid with strip counting to locate the fraction containing the radioactivity has been performed. These studies have demonstrated that the radioactive tracer is attached to the albumin molecule when tagged albumin has been employed as the radiopharmaceutical. Autoradiographic studies of synovial tissue removed at synovectomy following i.v. administration of ^{131}I HSA have demonstrated that most of the radioactivity is within the synovial membrane and not within surrounding tissue. When fluid has been aspirated from a knee with a positive localization, the count rate over the knee area is usually changed less than 25%, confirming that most of the localization is within the synovial membrane itself. The fact that the pattern of localization shown by the i.v. tracer actually demonstrates the synovial membrane can be documented by the pattern of the synovial membrane of the knee shown after intraarticular injection of a radiopharmaceutical (Fig. 6) and the work of Roucayrol.⁷

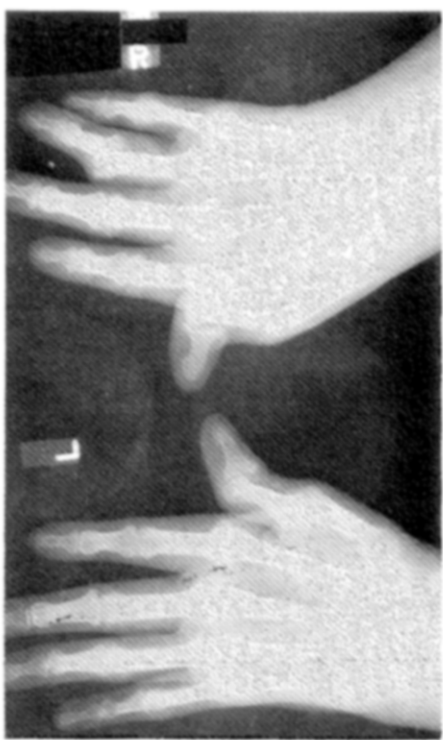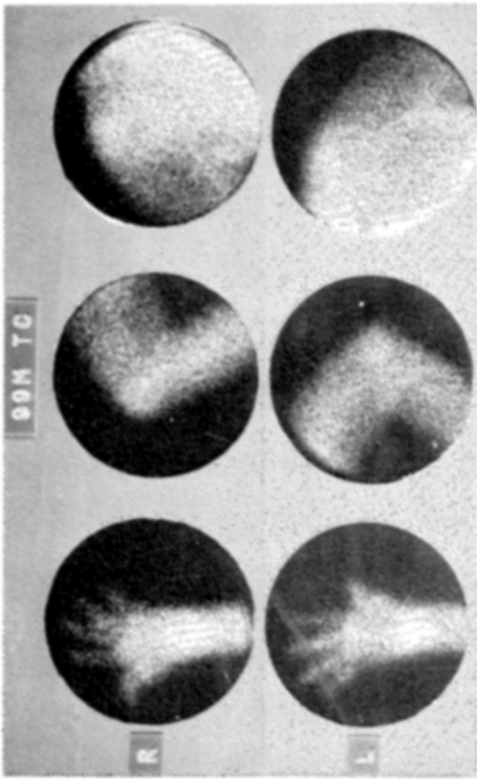
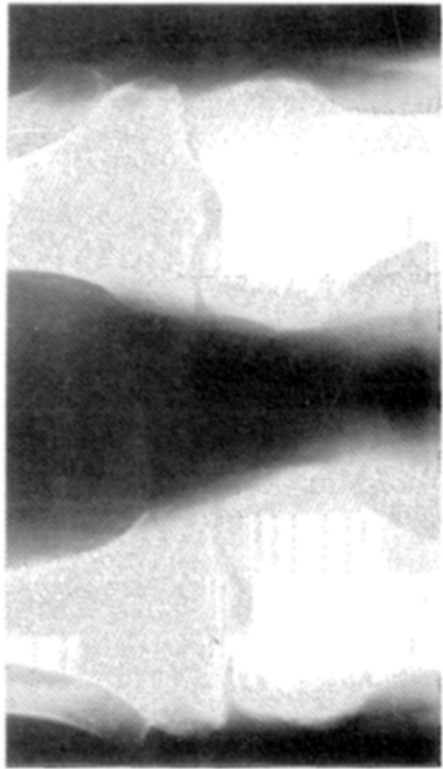
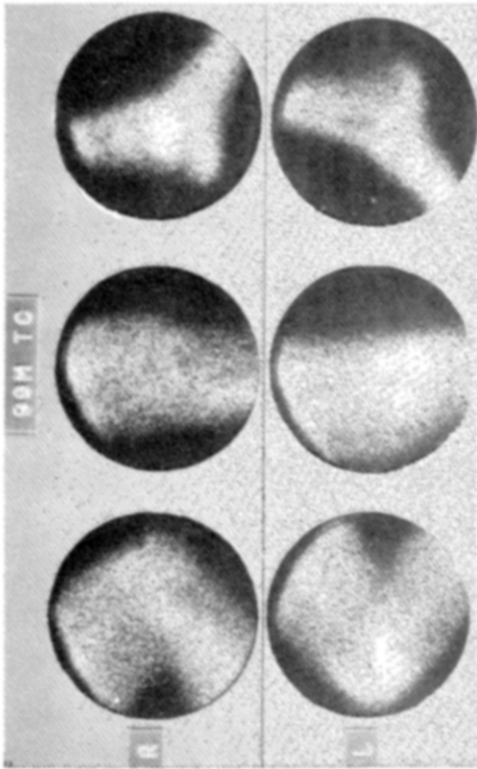
In our laboratory we have used intraarticular injection only to document that we are indeed seeing the synovial membrane with i.v.-injected tracers. In some cases of rheumatoid arthritis after intraarticular injection of ^{131}I HSA, there has been slow diffusion of the tracer throughout the synovial membrane. In other cases, there has been very rapid diffusion. The etiology for this difference has not been elucidated. For a definitive study of radiopharmaceuticals after intraarticular injection, reference is made to the work by Roucayrol et al.⁷ Intravenous administration has the advantage over intraarticular injection in that the i.v. route will show not only synovitis in a particular joint but will permit evaluation of the total pattern of synovitis in the joints of the extremities.

The possibility that use of several radiopharmaceuticals to evaluate this synovitis might give additional information has been provided by Martinez-Villaseñor et al.¹⁶ who noted that $^{99m}\text{TcO}_4$ and ^{113m}In do not always provide the same pattern in patients with rheumatoid arthritis. Possibly these tracers are measuring the degree of change in permeability and might be useful in staging the degree of synovitis. This concept needs further evaluation.

The dose schedule and radiation dose for radiopharmaceuticals employed for synovial membrane scanning after i.v. administration are listed in Table 1.

MATERIALS AND METHODS

When ^{131}I -labeled compounds are employed, the thyroid gland is blocked with Lugol's solution or potassium iodide 10 gtt \times 3 the day before the scan. For the ^{99m}Tc radiopharmaceuticals, the thyroid gland is blocked with 200 mg of potassium perchlorate given orally 1 hr before the tracer is injected. For the ^{113m}In , no thyroid blocking agent is required. With the ^{131}I -labeled tracers, the scans are usually started 2-6 hr after i.v. injection. For the radiopharmaceuticals using ^{131}I , rectilinear scanning is preferred. Scan-



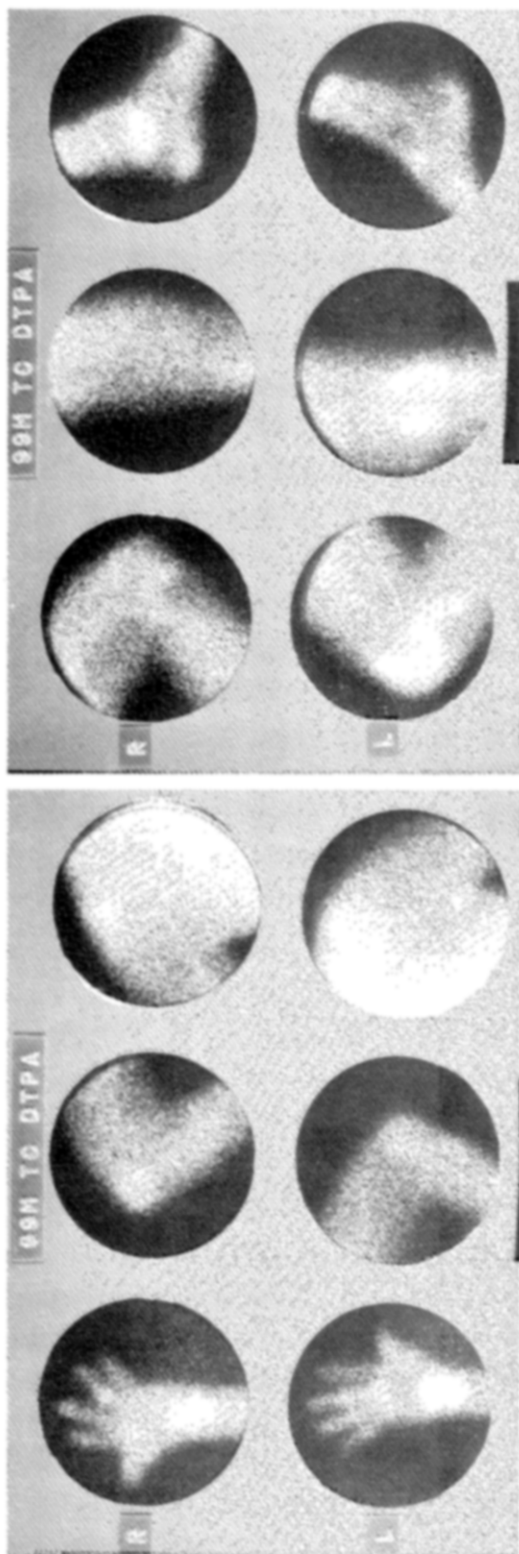


Fig. 4. $^{99m}\text{TcO}_4^-$ and ^{99m}Tc DTPA synovial membrane scan of patient with advanced rheumatoid arthritis. $^{99m}\text{TcO}_4^-$ scan was obtained first and ^{99m}Tc DTPA on day following. Pattern of localization for both tracers is essentially the same; ^{99m}Tc DTPA seems to show higher degree of localization in some synovial membrane areas. Note right fourth proximal interphalangeal joint and right elbow. PIP joint of each thumb shows no positive

localization although there are marked abnormalities on roentgenograms. When synovitis is burned out, synovial membrane scan shows only normal degree of localization. Roentgenogram of left knee shows lateral and medial erosion of tibia, correlating with markedly positive tracer localization in left knee shown on synovial membrane scans.

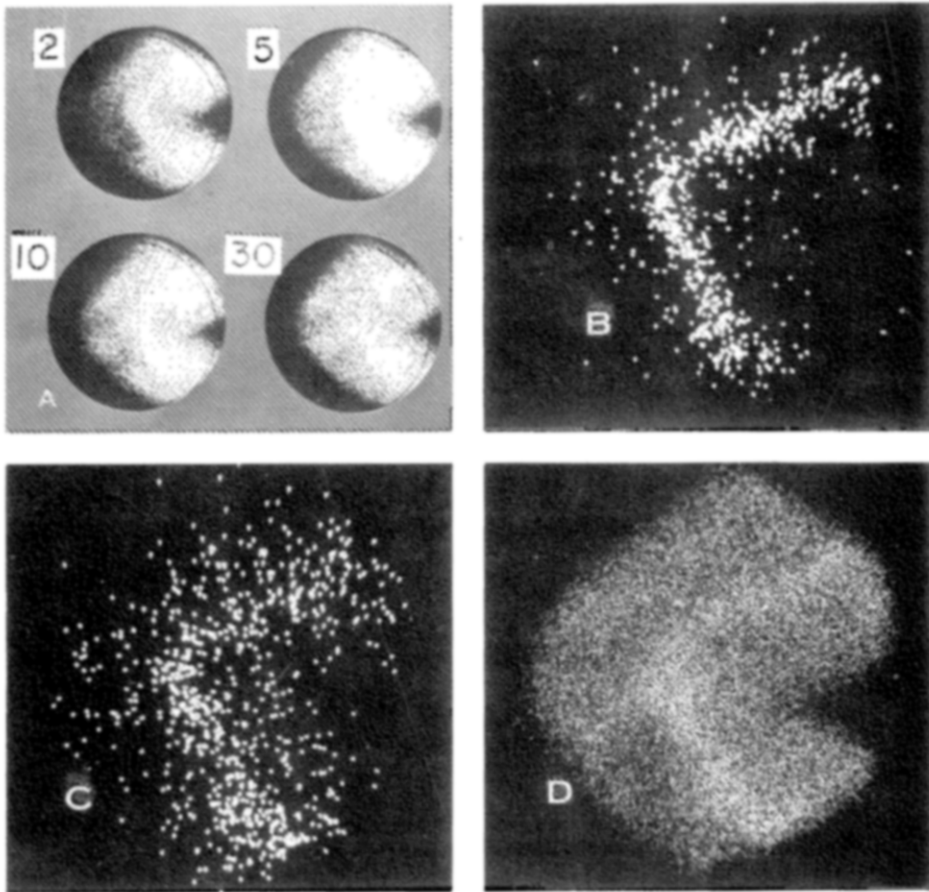


Fig. 5. Serial scintiphotos at 2, 5, 10, and 30 min after i.v. injection of 10 mCi of $^{99m}\text{TcO}_4$ demonstrate slow accumulation in normal synovial membrane (A). Two views from rapid-sequence, 35-mm study of perfusion of knee show that linear area of activity posterior on lateral view of knee is major vascular bundle: (B) Early arterial phase. (C) Intermediate arterial phase. (D) Pattern at 30 min.

ning with these tracers is usually limited to the hands and knees due to the long scan time. Care should be taken, when using a single detector rectilinear scanner, not to try to scan the hands on a table positioned over the knees as there may be detection of activity from the knees unless the table provides adequate half-value layers of shielding for the radionuclide employed. Detection of knee activity is especially a problem with ^{131}I tracers. Therefore, the hands are usually scanned by being placed on a table to the side of the patient rather than in front of him. When scanning the hands, it is preferable for the motion of the rectilinear scanner to be perpendicular to the digits rather than parallel. Use of a rectilinear scanner in this manner facilitates delineation of the interphalangeal joints.

With the ^{99m}Tc tracers, the scans are usually begun 5-30 min after i.v. injection. A stationary imaging device, such as an Anger camera, is preferable for ^{99m}Tc radiopharmaceuticals. This unit permits rapid evaluation of the joint areas and provides the capability for dynamic studies if indicated. Accessories for the stationary imaging units that permit quantitation of data and evaluation of areas of interest should improve the accuracy of the synovial membrane scan in the initial diagnosis of synovitis and in the determination of

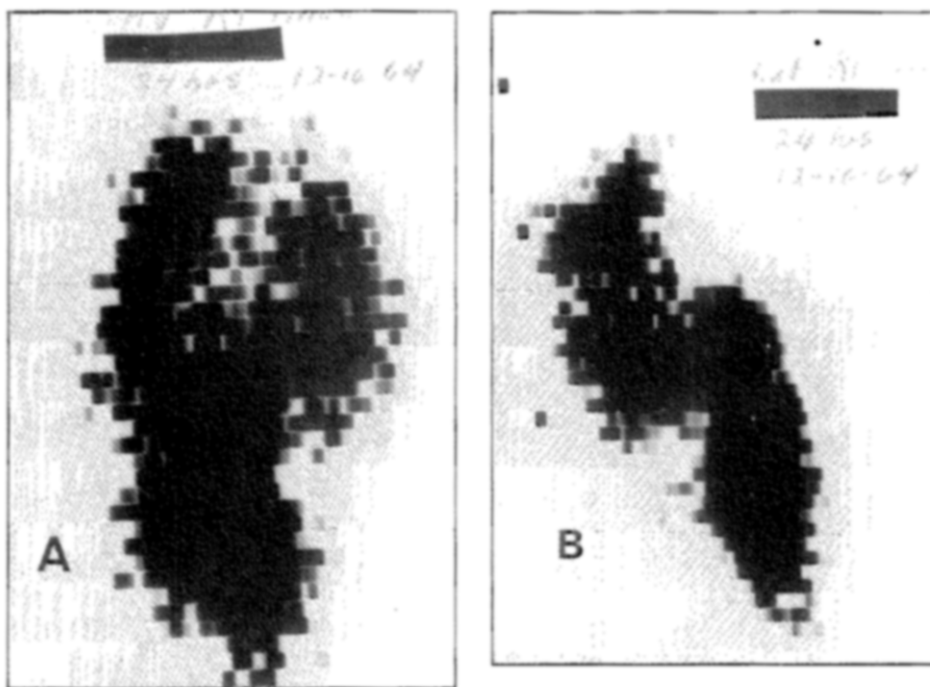


Fig. 6. Scan of right knee 24 hr after intraarticular injection of 15 μ Ci of 131 IHSA. Anterior view (A) and lateral view (B) from medial aspect indicate synovial membrane pattern which cor-

relates well with outline of synovial membrane after i.v. injection of radiopharmaceuticals used for demonstration of synovitis. Studies such as this one indicate that localization shown on i.v. studies is synovial membrane.

variation in degree of localization with time. Again, it is important that no other joint be superimposed within the field of view of the detector. Positioning the patient as shown in Fig. 7 will eliminate the problem of superimposition of joints. The use of the stretcher as illustrated is of particular value in patients with arthritic pain because patient motion must be minimal to achieve the required positions.

The 4000-hole, low-energy collimator is used with the Anger camera. The spectrometer range is set for 99m Tc and a 15% window is employed. Camera images are obtained by using a preset for 70,000 counts for the hands and knees. The contralateral joint employing the same view is then obtained for the same time required to obtain the preset number of counts on the initial view. For the elbows and ankles, 50,000 counts are accumulated.

Table 1. Radiopharmaceuticals for Synovial Membrane Scanning

Tracer	I.V. Dose of Tracer	Maximum Dose to Whole Body (mr)	Maximum Dose to Blood (mr)	Maximum Critical Organ (mr)
131 IHSA	25 μ Ci/10 lb	300	5400	Blood
131 Iodipamide	40 μ Ci/10 lb	30	450	Blood
99m Tc Albumin	1- 3 mCi	15	141	Blood
99m Tc pertechnetate	5-15 mCi	180	210	Stomach 3000 Colon 1700
99m Tc DTPA	5-10 mCi	160	160	Bladder 555
113m Indium pH 3.5	8-10 mCi	75	75	Blood

One-minute counts are used for each shoulder since in the shoulder area most of the count rate may come from activity within the lungs. The hips may also be studied by using a 1-min exposure. For the $^{99m}\text{TcO}_4$ tracer, it is particularly important to study one area and then the same area on the contralateral side as the next procedure. For ^{99m}Tc perfusion studies, serial scintiphotos with the polaroid camera are obtained as well as 35-mm images from a camera with the motor drive on the second oscilloscope. Use of a direct store accessory or computer readout would be a more accurate method of evaluation.

Since the dose schedule employed for brain scanning in our laboratory is the same as for synovial membrane scanning, patients coming for brain scanning can be used to establish the technique for synovial membrane evaluation. Careful selection of these patients provides an opportunity to obtain base line synovial membrane studies in patients with no history of joint complaints without administration of additional radiopharmaceuticals.

RESULTS

The localization of the tracers currently used for synovial membrane scanning is nonspecific. Almost all types of arthritic conditions have been reported to give a positive localization when the synovitis is active. The mechanism of the localization of the tracer in the abnormal synovial membrane appears to be due to a change in permeability and an increase in vascularity. If the localization were due to increased vascularity alone, the degree of localization in the synovial membrane would follow the concentration of the tracer in blood. Several experiments using external counting and perfusion studies with stationary imaging devices have shown that in the normal and abnormal synovial membrane there is an increase in activity in the synovial membrane while the blood concentration is falling (Fig. 5). For tagged albumin tracers, the peak activity in the synovial membrane occurs at 3-6 hr while with $^{99m}\text{TcO}_4$, the peak appears to be at 30-90 min. The perfusion studies indicate an accelerated localization with synovitis, probably due to increased vascularity. Still the activity over the synovial membrane rises while the plasma activity is falling.

Synovial membrane scanning has been limited to evaluation of synovial membrane areas of the extremities. With the availability of tomographic scanning, it might be possible to visualize the synovial membrane of the sacroiliac joints and the vertebral column. The first step in interpretation is recognition of the normal pattern. With the tagged albumin and ^{131}I iodipamide, the normal presents no problem since the normal synovial membrane is not outlined by these tracers. With $^{99m}\text{TcO}_4$, there is minimal localization in the normal synovial membrane in most cases. The degree of localization seems to vary, depending on the activity level of the person. There is not inconclusive evidence, but my impression is that a sedentary person will show minimal localization while an active person may have an almost abnormal scan. A change in activity or occupation, therefore, could produce some change in the $^{99m}\text{TcO}_4$ synovial membrane scan.

A greater variant, however, is the changing pattern of localization in the vascular and synovial membrane areas during the scan. It must be reemphasized that it is extremely important to proceed from one joint to the same view in the contralateral joint if degree of localization is to be compared from one view to another. When all of the peripheral joints are being studied, a standard sequence for the different views should be established so that the

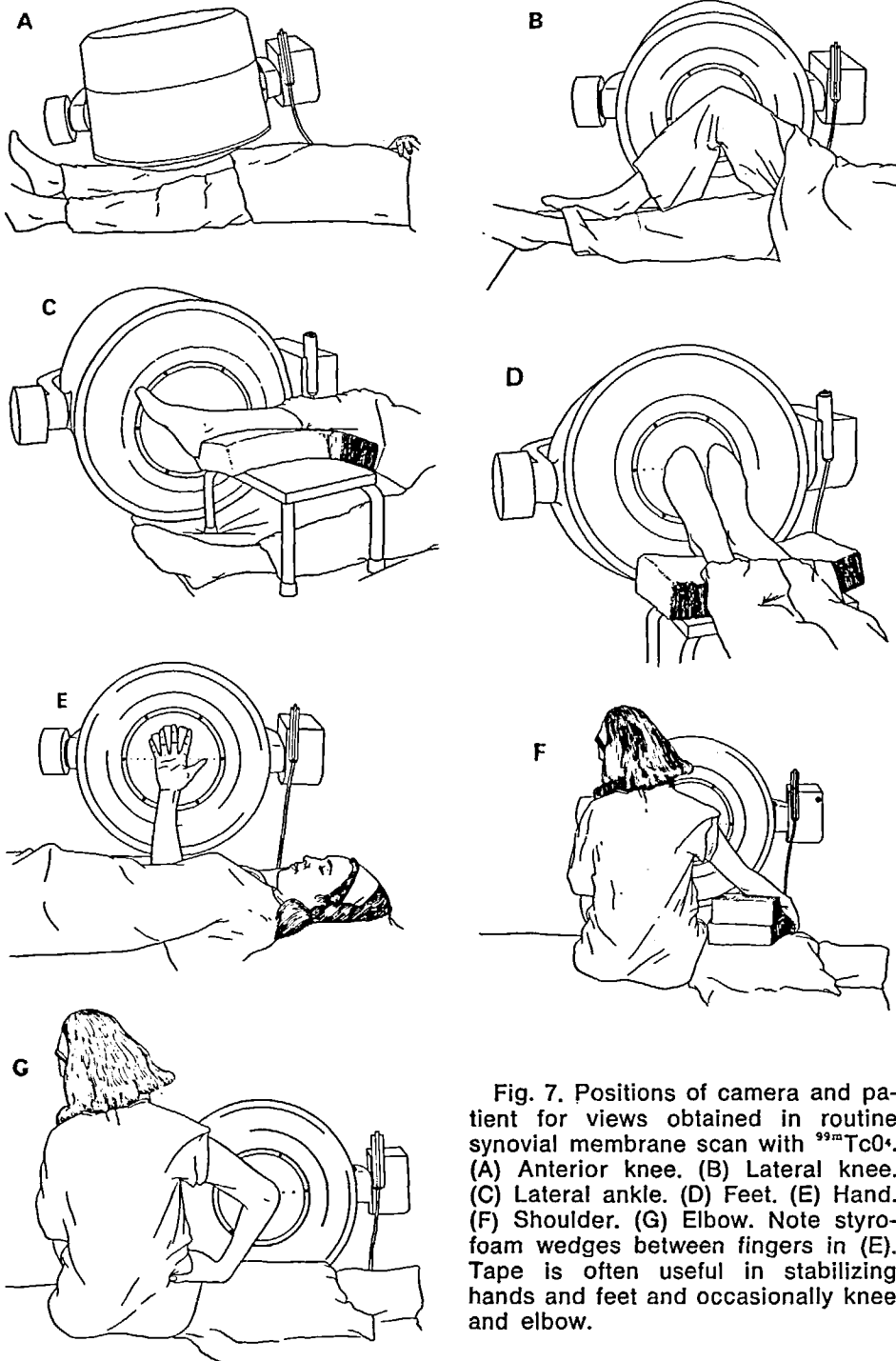


Fig. 7. Positions of camera and patient for views obtained in routine synovial membrane scan with $^{99m}\text{TcO}_4$. (A) Anterior knee. (B) Lateral knee. (C) Lateral ankle. (D) Feet. (E) Hand. (F) Shoulder. (G) Elbow. Note styro-foam wedges between fingers in (E). Tape is often useful in stabilizing hands and feet and occasionally knee and elbow.

different joints will be scanned at approximately the same time after injection in all patients. After 1 hr there is localization of $^{99m}\text{TcO}_4$ in normal synovial membrane.

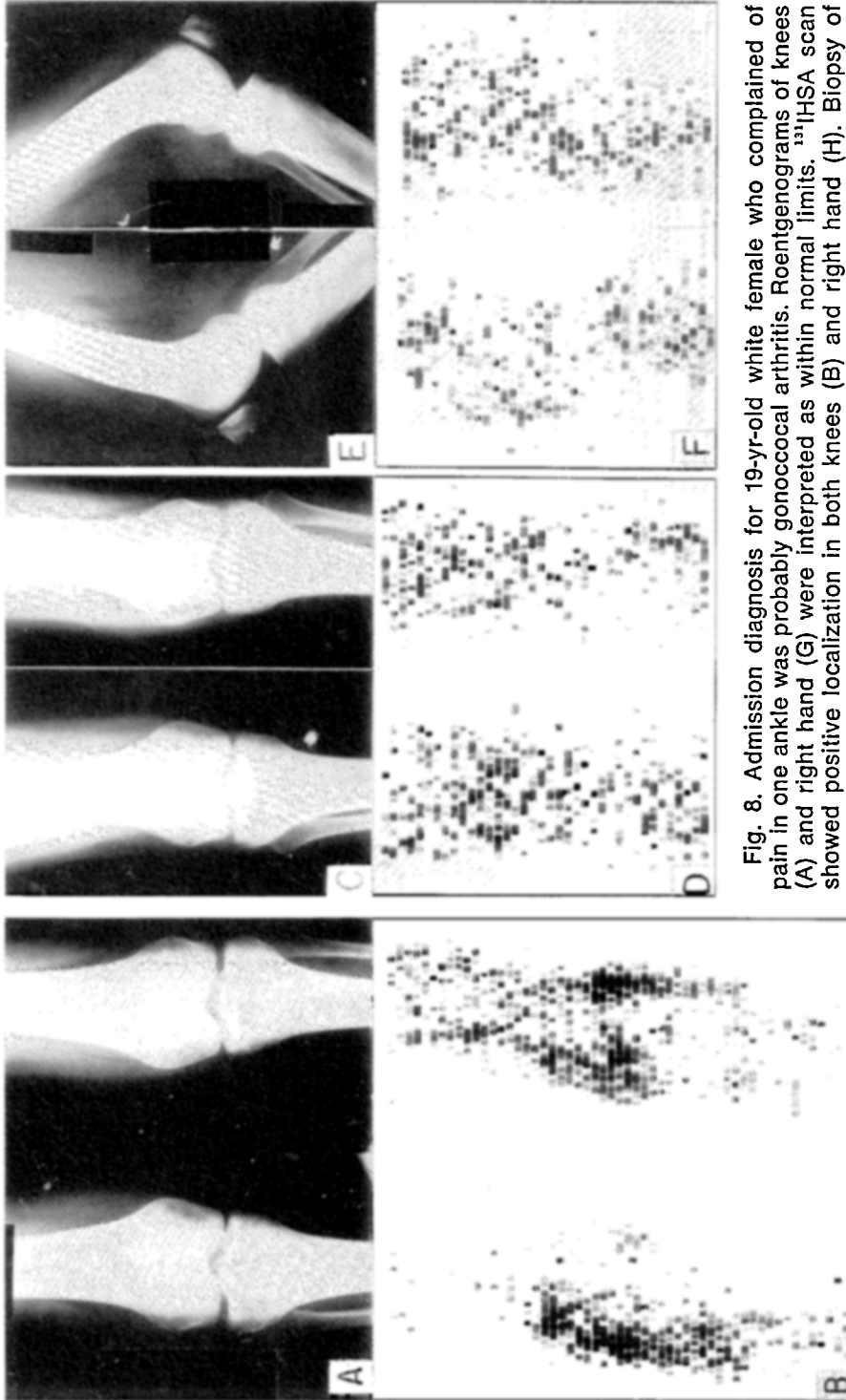
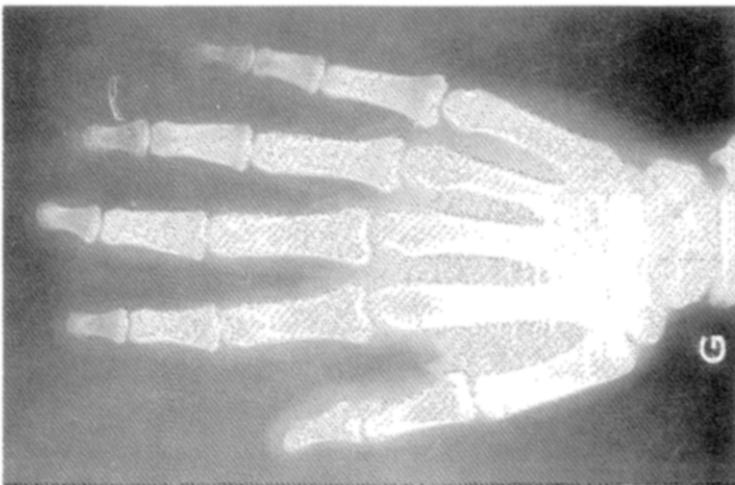
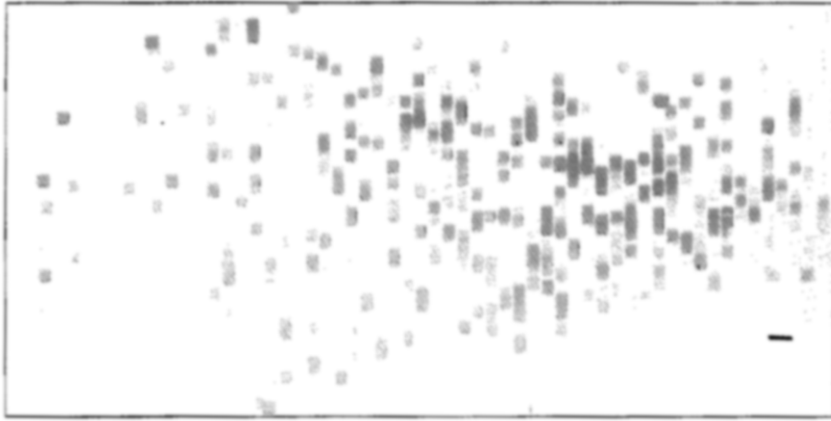
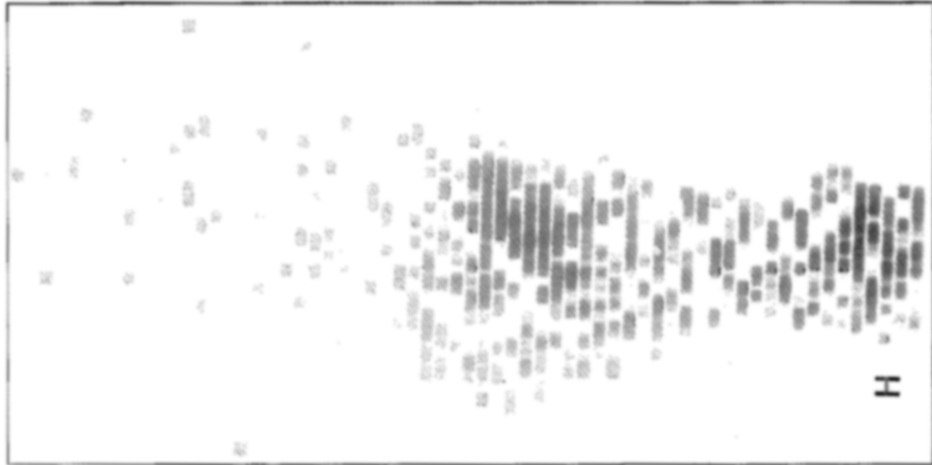


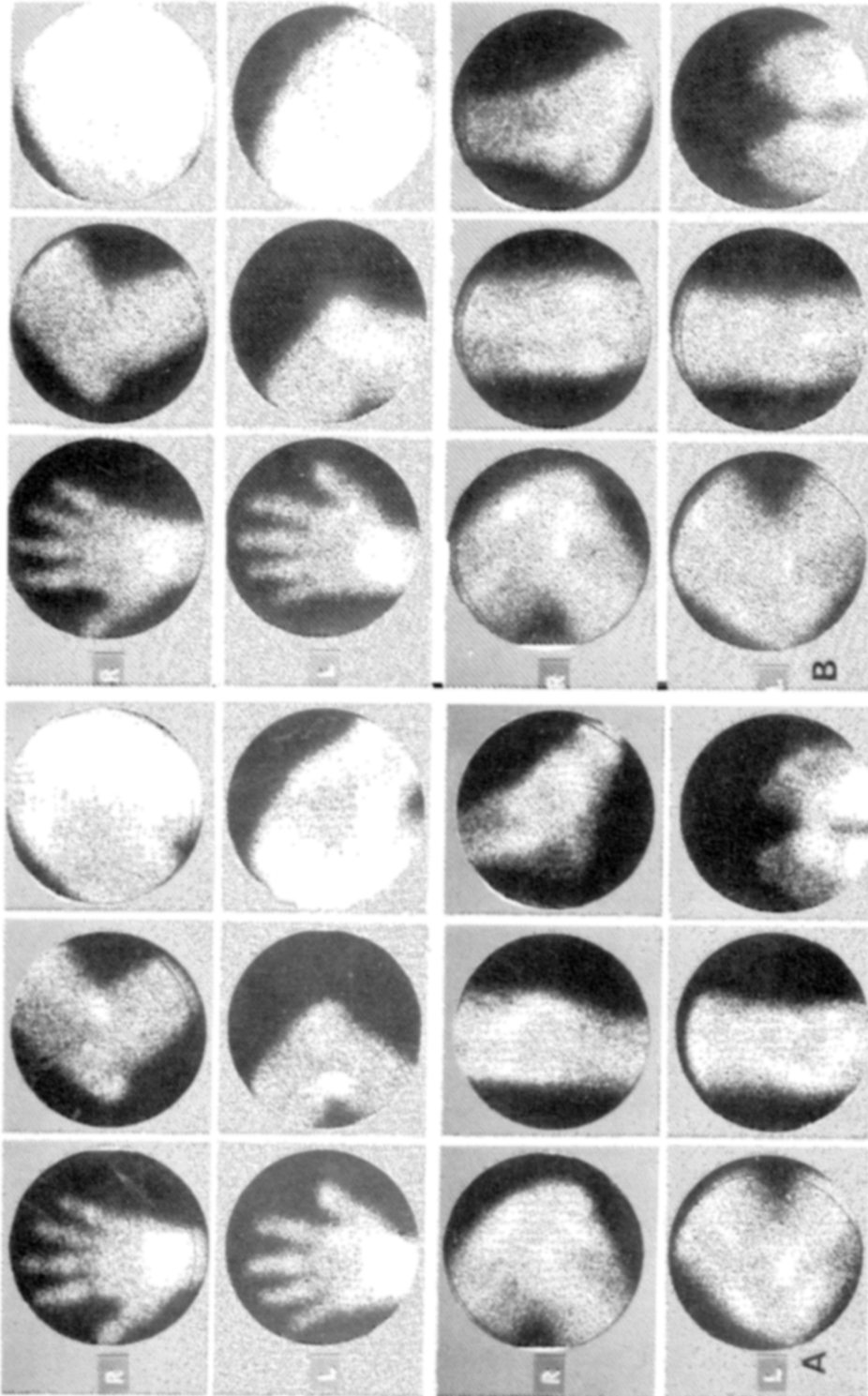
Fig. 8. Admission diagnosis for 19-yr-old white female who complained of pain in one ankle was probably gonococcal arthritis. Roentgenograms of knees (A) and right hand (G) were interpreted as within normal limits. ¹²⁵I-HSA scan showed positive localization in both knees (B) and right hand (H). Biopsy of synovial membrane of right knee and of right hand gave diagnosis of polyarthritis. Roentgenograms of knees after 1 yr of corticosteroid therapy were



interpreted as showing osteoporosis (G) and (E). It could not be determined if change was from therapy or from progression of disease. Synovial membrane scan at that time showed normal pattern in knees (D and F) and right hand (I). Normal



scan correlated with patient's statement of no joint pain. No joint abnormality was detectable on physical examination.



See legend on facing page.

A guideline for an abnormal scan is that the degree of localization must be greater than in adjacent normal vascular areas. For example, on the lateral view of the knee, the localization in the synovial membrane should not exceed the activity in the posterior vascular bundle (Figs. 3 and 5). In children, the localization of $^{99m}\text{TcO}_4$ in the normal epiphysis must not be confused with abnormal localization in the synovial membrane. Accessories for the stationary imaging unit that will permit quantitation of the degree of localization in synovial membrane scans should significantly increase the diagnostic accuracy of the initial scan. Such equipment would markedly improve the measurement of response to therapy or progression of disease as demonstrated by repeat scans.

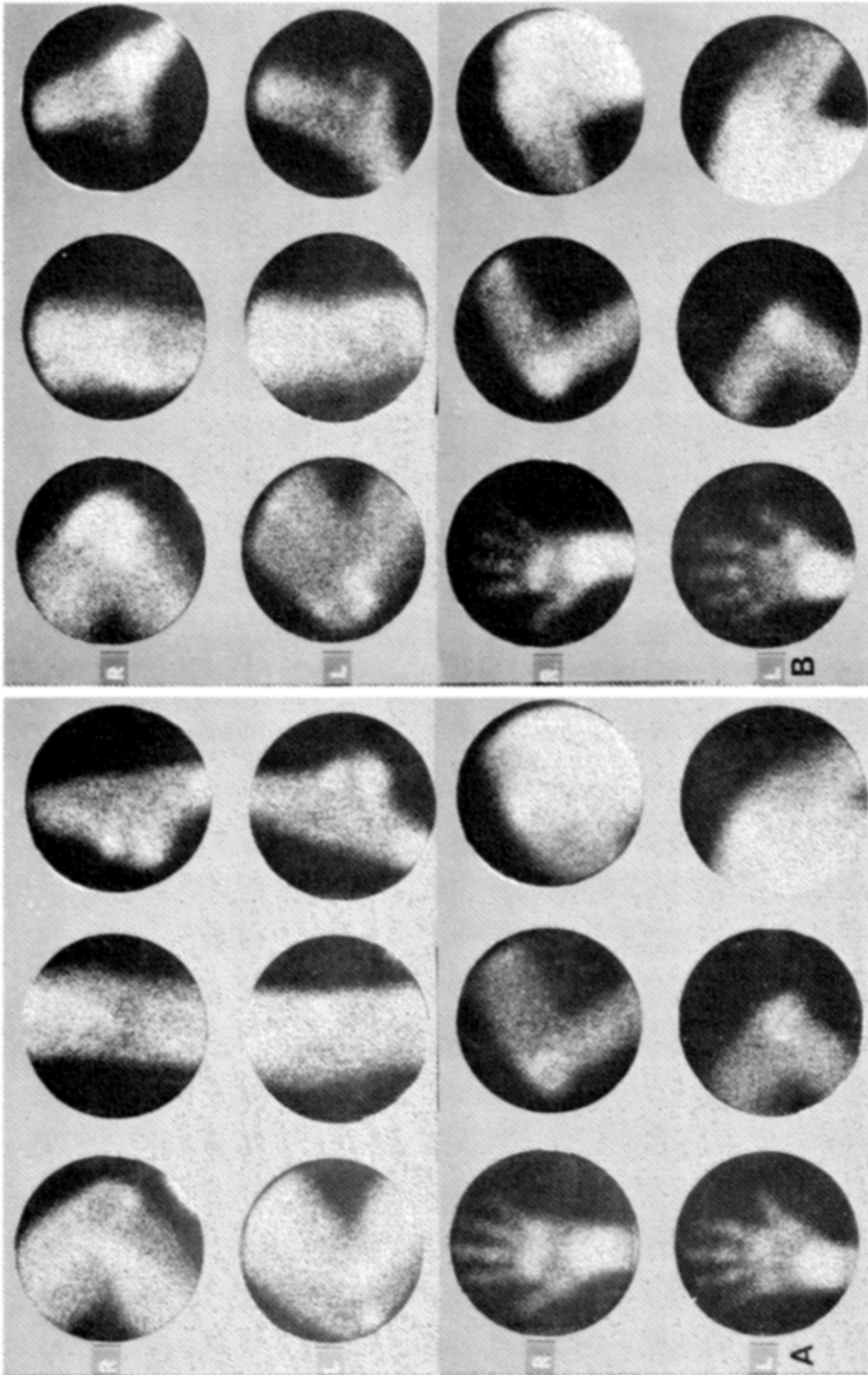
The best source of normal synovial membrane scans in most laboratories will be brain scan patients. Several of the cases illustrated have been scanned with $^{131}\text{IHSa}$, but the same pattern would be obtained with $^{99m}\text{TcO}_4$. A typical example of advanced rheumatoid arthritis is shown in Fig. 4. This case also demonstrates that, when the synovitis burns out, the localization returns to normal. An excellent demonstration that the synovial membrane scan can demonstrate the extent of synovitis is shown by the $^{131}\text{IHSa}$ scan in Fig. 8. The demonstration of the extent of the synovial membrane by a scan aids the surgeon in planning a biopsy or synovectomy.

Figure 8 is a $^{131}\text{IHSa}$ study that demonstrates (as does Fig. 12B) that the synovial membrane scan can show that the synovitis is often more extensive than expected from the patient's predominate complaint. McCarty²² and Sholkoff¹⁸ have confirmed our observations that the synovial membrane scan can detect synovitis before it becomes clinically evident by other means. In experimental animals using inoculation of bacteria to produce an infectious arthritis, Sholkoff et al.²³ documented that the synovial membrane scan with $^{99m}\text{TcO}_4$ was positive before the arthritis became clinically evident. Figure 8 documents the problem of measuring arthritis roentgenographically for patients receiving steroids. Here the scan has a clear advantage as an objective method for the evaluation of the degree of synovitis.

Gout can show a scan pattern that can easily be confused with rheumatoid arthritis (Fig. 9). Fortunately, gout and rheumatoid arthritis can usually be separated easily by laboratory tests. The follow-up scan documents the response to therapy in this case of gout and shows that even though the patient is essentially asymptomatic, some residual synovitis may persist. When the synovitis is truly quiescent, the localization will return to normal.

Early Reiter's disease and rheumatoid arthritis are difficult to differentiate by roentgenographic and laboratory tests. The synovial membrane scan can aid in this differentiation (Fig. 10). Another pattern shown by Reiter's

Fig. 9. $^{99m}\text{TcO}_4$ synovial membrane scan in patient with acute gout. (A) Scan provides objective documentation of pattern of synovitis. Localization in each antecubital fossa on initial scan is due to slight infiltration at time of injection of $^{99m}\text{TcO}_4$. (B) Repeat scan after 3 mo of therapy when patient was essentially asymptomatic still shows positive localization in most synovial membrane areas. Degree of localization has markedly decreased. There was no infiltration at time of injection for second scan.



See legend on facing page.

disease is marked localization in the heel and sole of the foot. This pattern is seldom seen in rheumatoid arthritis.

Areas of osteoarthritis may or may not show a positive localization. If there is a positive localization, it is usually a limited area, confined to the region where there is roentgenographic evidence of disease. Rheumatoid arthritis, however, may start as simply one area of localization in a synovial membrane. This pattern has been noted most frequently in the knee joint. Serial scans will show progression to involve the whole synovial membrane area. Osteoarthritis will usually retain the same pattern on serial scans. Figure 11 is a typical case of osteoarthritis.

The cases in Fig. 12 demonstrate the ability of the synovial membrane scan to separate nonarthritic joint complaints from those with early synovitis undetected by other methods. Our experience and that of others has been that the synovial membrane scan is about 30% more accurate than roentgenographic evaluation in detection of synovitis. If applied only to problem cases, the accuracy would probably be higher. False positives do occur, but they are rare (less than 2-5%). Most of our problems occurred before we recognized fully the pattern of normal localization with $^{99m}\text{TcO}_4$. As Figs. 8 and 12B demonstrate, what could appear to be false positive localizations, upon biopsy or follow up will frequently prove to be early detection of arthritis. McCarty,²² Martinez-Villaseñor,¹⁶ and Sholkoff¹⁸ have reported similar experiences.

In a few cases, a pattern noted that remains unexplained is that of hot fingertips with an otherwise normal scan. These have occurred in young patients with morning stiffness or migratory joint complaints. To date, none of these cases has developed a definite arthritis. Sholkoff has reported cases of lupus erythematosus with hot fingertips, but these cases have also had other areas of abnormal localization.¹⁸

COMPARISON WITH OTHER METHODS

The synovial membrane scan is an objective method for detecting and documenting synovitis in almost all forms of arthritis. It is more accurate than the roentgenogram in detecting early synovitis and is more sensitive in measuring the course of the patient's disease. The synovial membrane scan is more objective and actually more accurate, especially in evaluation of the knee, than is the physical examination. There has been excellent correlation of the synovial membrane scan with patient complaints in true arthritis. The scan cannot pinpoint the type of arthritis as accurately as laboratory tests, but the determination that synovitis is present and evaluation of the pattern of involvement are frequently helpful in establishing the correct diagnosis. The synovial membrane scan can at times indicate the best site for biopsy. A preliminary

Fig. 10. (A) Typical synovial membrane scan for patients with Reiter's disease. Note that predominate localization in knees would correspond to site of tendon insertions and very positive localization in Achillies tendon. Pattern in hands could be that of rheumatoid arthritis or gout (B) Patients with rheumatoid arthritis can show localization in tendons, but degree of localization is usually less and overall pattern is more typical of rheumatoid arthritis with knee and tarsal involvement.

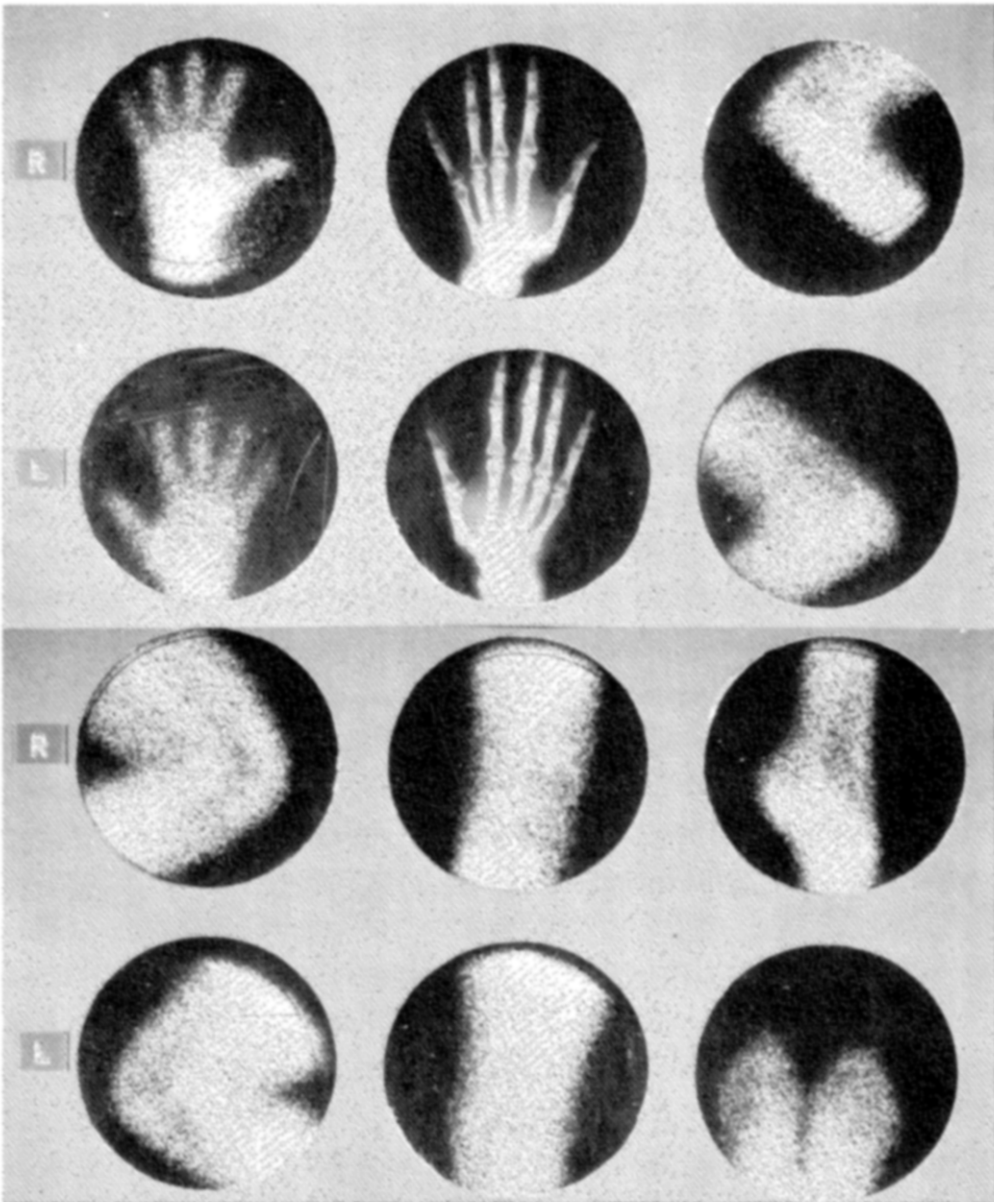


Fig. 11. Osteoarthritis usually shows positive synovial membrane scan only in areas where there is evidence of osteoarthritis on roentgenograms. This patient complained of pain at base of right thumb. Roentgenogram and $^{99m}\text{TcO}_4$ were both positive in this area and other joint areas were normal on both studies.

comparison with thermography suggests that the synovial membrane scan is more sensitive in detection of synovitis, especially in the knee. Thermography shows a more superficial pattern, while the scan can demonstrate the deep synovial area.²⁴

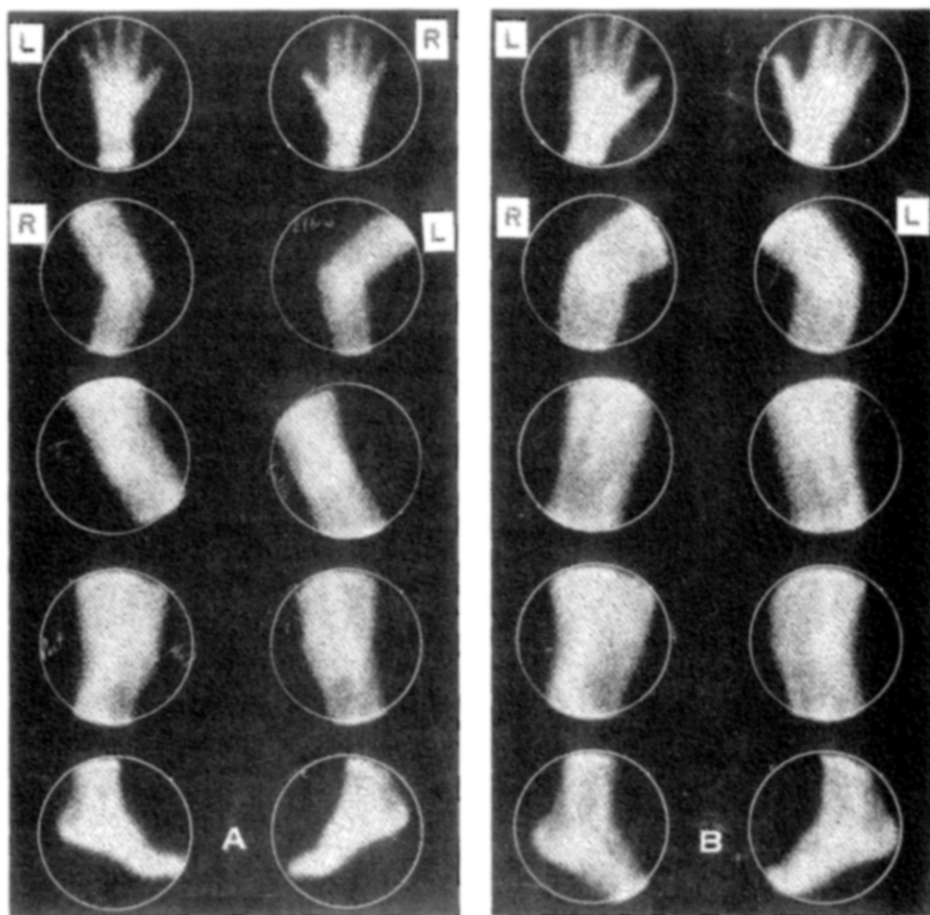


Fig. 12. $^{99m}\text{TcO}_4^-$ synovial membrane scans of two patients with joint pain and normal roentgenograms. In both patients laboratory studies were normal and physical examination was equivocal for arthritis. (A) Normal pattern. Follow-up on this patient for 1 yr has shown no objective evidence of arthritis. (B) Positive localization in right third MCP joint and in both elbows. Scan confirmed that pain in right third MCP was due to synovitis, and detected synovitis in elbows 1 mo before it became significant complaint. Rheumatoid arthritis was confirmed by laboratory studies 1 mo after scan gave first objective evidence of synovitis.

REFERENCES

1. Ahlström, S., Gedda, P. O., and Hedberg, H.: Disappearance of radioactive serum albumin from joints in rheumatoid arthritis. *Acta Rheum. Scand.* 2:129, 1956.
2. Harris, R., Millard, J. B., and Banerjee, S. K.: Radiosodium clearance from the knee joint in rheumatoid arthritis. *Ann. Rheum. Dis.* 17:189, 1958.
3. Rodnan, G. P., and Maclachlan, M. J.: The absorption of serum albumin and gamma globulin from the knee joint of man and rabbit. *Arthritis Rheum.* 3:152, 1960.
4. St. Onge, R. A., Dick, W. C., Bell, G., and Boyle, J. A.: Radioactive xenon ^{133}Xe disappearance rates from synovial cavity of

- human knee joint in normal and arthritic subjects. *Ann. Rheum. Dis.* 27:163, 1968.
5. Dick, W. C., et al.: Clinical studies on inflammation in human knee joints: Xenon (^{133}Xe) clearances correlated with clinical assessment in various arthritides and studies on effect of intra-articularly administered hydrocortisone in rheumatoid arthritis. *Clin. Sci.* 38:123, 1970.
 6. —, et al.: Derivation of knee joint synovial perfusion: Using xenon (^{133}Xe) clearance technique. *Ann. Rheum. Dis.* 29:131, 1970.
 7. Roucayrol, J. C., Delbarre, F., Ingrand, J., and Aignan, M.: Arthroscintigraphies (Scintigraphy of the joints). In *Medical Radioisotope Scintigraphy*, Vol. II. Vienna, International Atomic Energy Agency, 1968, p. 281.
 8. Limentani, A., Paleari, G. L., and Fuoco, L.: Research on the use of ^{131}I labeled albumin in the study of dynamics of the synovial fluid (in Italian). *Reumatismo* 15:26, 1963.
 9. Maxfield, W. S., Weiss, T. E., Murison, P. J., and Hidalgo, J. U.: Localization of I.H.S.A. in rheumatoid joints. *J. Nucl. Med.* 5:373, 1964.
 10. Weiss, T. E., Maxfield, W. S., Murison, P. J., and Hidalgo, J. U.: Iodinated human albumin (^{131}I) localization studies of rheumatoid arthritis joints by scintillation scanning. *Arthritis Rheum.* 8:976, 1965.
 11. —, —, —, and —: Scintillation scanning in rheumatoid arthritis. *Southern Med. J.* 59:484, 1966.
 12. Maxfield, W. S., Weiss, T. E., Murison, P. J., Tutton, R. H., and Hidalgo, J. U.: Scintillation scanning of the rheumatoid joint. In *Croll, M. M. and Brady, L. W. (Eds.): Recent Advances in Nuclear Medicine*. New York, Appleton-Century-Crofts, 1966, p. 224.
 13. —, —, Tutton, R. H., and Hidalgo, J. U.: Detection of arthritis by joint scanning. In *Medical Radioisotope Scintigraphy*, Vol. II. Vienna, International Atomic Energy Agency, 1968, p. 307.
 14. —, —, Murison, P. J., Tutton, R. H., and Hidalgo, J. U.: Joint scanning with labeled albumin. In *Hidalgo, J. U. (Ed.): Symposium on Computer and Scanning Techniques*. New York, Society of Nuclear Medicine, 1968, p. 143.
 15. Whaley, K., et al.: Articular scan in patients with rheumatoid arthritis: Possible method of quantitating joint inflammation using radiotechnetium. *Clin. Sci.* 35:547, 1968.
 16. Martinez-Villaseñor, Bush, P., and Katona, G.: Scintigraphy by means of radioisotopes of short half-life for diagnosing diseases of the joints. In *Medical Radioisotope Scintigraphy*, Vol. II. Vienna, International Atomic Energy Agency, 1968, p. 295.
 17. Maxfield, W. S., and Weiss, T. E.: Technetium- $^{99\text{m}}$ joint images. *Radiology* 92:1461, 1969.
 18. Sholkoff, S. D., and Glickman, M. G.: Scintiphotographic evaluation of arthritic activity. *Invest. Radiol.* 4:207, 1969.
 19. Alarcon-Segovia, D., Assad-Morell, J. L., Cervantes, A., and Tovar, E.: Painful Baker's cysts: Differential diagnosis by scintillation scanning with technetium. *JAMA* 210:553, 1969.
 20. McCarty, D. J., Polcyn, R. E., Collins, P. A., and Gottschalk, A.: $^{99\text{m}}$ Technetium scintiphotography in arthritis. I. Technic and interpretation. *Arthritis Rheum.* 13:11, 1970.
 21. Maxfield, W. S., Shuler, S. E., and Weiss, T. E.: $^{99\text{m}}$ Tc DTPA for synovial membrane scanning. In *Proceedings of Meeting of Chapter Nuclear Medicine*, March 20, 1971. In press.
 22. McCarty, D. J., Polcyn, R. E., and Collins, P. A.: $^{99\text{m}}$ Technetium scintiphotography in arthritis. II. Its nonspecificity and clinical and roentgenographic correlations in rheumatoid arthritis. *Arthritis Rheum.* 13:21, 1970.
 23. Sholkoff, S. D., Glickman, M. G., Shachter, J., and Rowland, M.: External counting and scintiphotography in rabbits with arthritis. *Arthritis Rheum.* 12:220, 1969.
 24. Maxfield, W. S., Weiss, T. E., and Shuler, S. E.: Comparison of synovial membrane scanning to thermography in evaluation of arthritis. Unpublished.