

HYPERBARIC OXYGEN IN ACUTE ISCHEMIA AND CRUSH INJURY

Venneman I., Colignon M., Lamy M.

Department of Anesthesiology, University of Liege, Belgium.

Carlier A., Lejeune G.

Department of Surgery, University of Liege, Belgium.

Trauma may produce a very important tissular destruction with severe problems at bones, muscles and, of course, acute insufficiency both arterial and venous, of parts of a limb or of an entire limb.

In all patients with so severe trauma, the blood supply to the crushed area is compromised and the survival of the limb is not guaranteed.

So, in the treatment of a limb injury, priority should be given to the restoration of circulation. Surgical repair is of course usually required.

The survival of a limb depends on anatomical reconstruction of torn blood vessels and on the period of time between injury and repair. The time limit of reimplantation at room temperature commonly accepted is 5 to 6 hours and the twelfth hour may be the point of irreversibility : anoxia and ischemia are severe and gangrene may develop despite apparently successful restoration of circulation.

HBO can be helpful in reconstructive vascular surgery, in maintaining the limb alive while awaiting definitive surgery (ischemic limb and muscle can be salvaged even after as long as 36 hours) or in supporting the limb immediately post-surgery until arterial blood flow improves.

THEORIC BASES OF HBO USE

Following acute ischemia of a limb, a serie of pathological events occur in the ischaemic tissues, probably set in motion by anoxia metabolic changes due to malperfusion of the muscles which are the most sensitive to anoxia in a limb (normal tissues, skin and cartilage can tolerate anoxia insults for a longer time).

Muscle

The effect of ischemia on muscle appear to be related to the ischemic time. The initial effect on energy metabolism as measured by tissue ATP, blood and muscle pH is the cessation of oxidative phosphorylation. The conversion of ADP to ATP is markedly reduced and lactate is produced. When these conditions persist, the integrity of the sodium pump in cell membranes becomes compromised resulting in loss of intracellular potassium and gain of sodium and chloride ions into the cell. This results in an increase of intracellular osmotic pressure with a shift of water into the cell which causes an oedema of the cell.

Capillary

Following acute ischemia of a limb, there are prolonged and progressing changes in the microcirculation.

There is a vasodilation at the pre-injury level : this increased blood flow is an autoregulation mechanism to compensate for hypoxia (metabolites from acidosis are vasodilators).

HBO THERAPY FOR TRAUMATIC ISCHEMIA AT THE UNIVERSITY OF LIEGE

Since 1971, a department of microsurgery has been developed in our hospital and we receive patients from the whole country, with very important traumas of limbs.

Since January 1978, we have treated 390 patients. The pathology encountered was traumatic with important tissue destruction, devascularisation, skin and muscle necrosis, open fractures, contaminated wounds with foreign bodies, compartment syndrome and sometimes complete section of a limb.

The population in question is a young one : 60 % of the patients are under 40 years old and the mean age is 29 years old. Automobile and motorcycle accidents are responsible for about 60 % of the cases; 40 % are domestic or industrial.

The localization of the injury was :

- lower limb : 58 %
- upper limb : 26 %
- abdomen : 11 %
- chest : 3 %
- head : 2 %

85,5 % of the patients underwent surgery before HBO therapy : crush injuries were debrided, compartment syndrome decompressed, fractures stabilized, muscle vessels and nerves repaired. Often, skin grafts are necessary. Frequent returns to the operating room for dressing changes under anesthesia and additional debridement were often necessary.

HBO therapy was performed in all the patients. We use a monoplace chamber from the Draeger Company, compressed with pure oxygen. The patients are treated during one hour at 3 ATA. No symptoms of oxygen toxicity occurred. The first HBO session was usually performed just after surgery, the second one 8 hours later, the third 16 hours later. The patients underwent 2 sessions daily during the following 2 days and one session daily during 3 or 4 days.

In some cases, HBO sessions has been necessary during 2 or 3 weeks or more, because of massive crush syndrome, ischemic flaps or osteomyelitis. The number of HBO treatments per patient ranged from 3 to 45; the mean is 12 sessions.

Only one of the 390 patients treated with HBO has developed gas gangrene.

collagen is necessary to form a matrix for the new capillaries which carry additional nutrients and O₂ to the wounds and injured tissues. It seems that the major stimulant of angiogenesis is hypoxia but the deposition of collagen is increased with hyperoxia. In the phenomenon of reimplantation of limb, the anoxic period before surgery provides stimulus for angiogenesis and HBO therapy apparently provides the O₂ stimulus for collagen synthesis.

- c. O₂ is also necessary to the fibroblastic proliferation, migration and activity (collagen synthesis for example). A specific P_{O₂} is required for cell proliferation and another one for collagen production; and this P_{O₂} is in relation with the distance between fibroblasts and capillaries which supply oxygen. The rate at which the edge of granulation tissue advances is limited essentially by its oxygen supply. If more O₂ is made available, fibroblasts will migrate further from the last functioning capillary and a wider zone of fibroblasts will produce collagen at a faster rate. Then, there is good evidence to indicate that healing can be accelerated by the addition of O₂ and then by HBO, this one seems to be necessary especially in ischemic or infected wounds.
6. At last, HBO has beneficial effect on infection. Once the skin is broken, micro-organisms contaminate the exposed tissues when tissue O₂ tensions are below 40 torr, leucocytes are unable to employ oxygen dependent killing mechanisms. The mechanisms most profoundly affected are leucocytes migration and white cells killing involving superoxyde and hydrogen peroxyde. In addition, the bloodstream transport of antibodies, immunoproteins and leucocytes to the site of infection is reduced. Hyperoxygenation improves white cells function until capillary growth restores blood supply.
HBO has also a direct effect on micro-organisms : anaerobic organisms such as Clostridia are inhibited by increased O₂ tensions; growth of some aerobic organisms is also slowed by HBO.
HBO eliminates gaz gangrene and prevents aerobic infections when used in acute trauma.

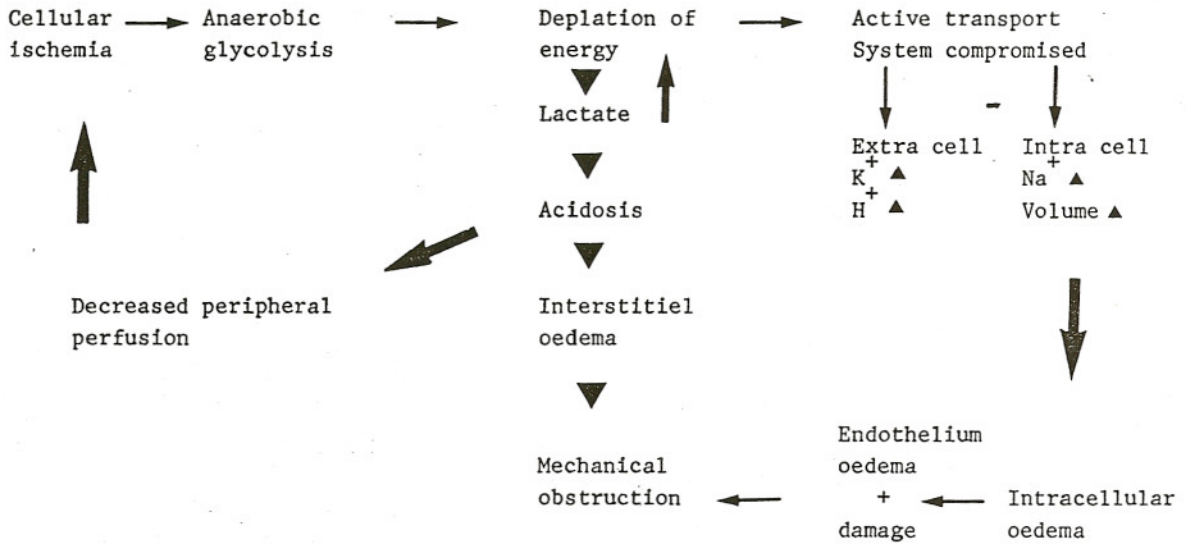
The active processes in the endothelial cells of capillaries slow down as in muscle cells and this results in metabolic and morphologic changes. The permeability of capillary endothelium to water, electrolytes and organic substances increases. This produces oedema of the ischemic tissues.

When the circulation is restored, there is a sudden increase of the pressure and volume of the blood in the regional vascular bed and an opening of physiological arterio-venous shunts. Owing to this increase of pressure and to persisting damage to the capillary walls, local oedema of the ischemic tissue persists and increases, whereby the capillary bed is compressed, local circulation is further impaired and ischemia is enhanced.

EFFECTS OF HBO

1. HBO allows oxygenation of tissues even when the blood flow is disturbed. O₂ physically dissolves in plasma in direct proportion to its partial pressure. At 3 ATA, the diffusible O₂ and O₂ tension in the blood is increased 20 times (17 times at 2.5 ATA). It is sufficient to sustain life in the complete absence of functional hemoglobine. The gradient for O₂ diffusion is increased and the O₂ supply to the cells is improved.
2. In addition, HBO is helpful in the oxidation of pyridine nucleotide and prevents the escape of acid hydrolase from lysosomes. If irreversible changes have already taken place in the cells, HBO has no effect or can even be detrimental by enhancing toxic oxygen forms production.
3. At the capillary level, the considerable elevation of the arterial pressure of O₂ provides protection against the vicious circle established by anoxia because of vasoconstriction : treatment with HBO at 2 ATA reduces the blood flow by approximatively 20 % (18.9 %). (There is less diapedesis and bleeding into the injured area; reduction of blood flow is well compensated by the hyperoxygenation). Otherwise, the hyperoxygenation has also its effect on the endothelial cells which regain their normal membrane structure and permeability. These are probably the mechanisms for oedema reduction.
4. If the blood circulation has not been reestablished or thrombus formation is present, then, in spite of a high partial pressure of O₂ in the arterial blood, sufficient O₂ cannot pass into the rejoined limb and the muscle cells still have a poor supply of O₂. Hence, it is imperative that the vessels should be successfully rejoined before HBO is restored to, at least collateral circulation must partially exist.
In the case of non existence of major blood vessels, HBO is expected to help the demarcation process between living and dead tissues.
5. Another beneficial effect of HBO is that the oxygenation activates cellular metabolic processes that are O₂ dependent; O₂ is essential to healing.
 - a. Granulation tissue consumes O₂.
 - b. O₂ is essential for the collagen synthesis :
Molecular O₂ is essential for the hydroxylation of proline and lysine during collagen synthesis. Without molecular O₂, this enzymatic reaction does not occur and collagen production is stopped. The

VICIOUS CIRCLE OF ANOXIA



CONCLUSIONS

Although HBO therapy has not been studied randomly, the benefit is obvious during the different sessions : improvement of oxygenation of the transplanted areas with reduction of cyanosis. A prospective randomized study should be done in the future to confirm the clinical benefit of this adjunctive therapy.

REFERENCES

1. BRANEMARK PI, EKHOLM B, ALBREKTSSON, LINDTROM, LUNDBORG, LUNDSKOG.
Tissue Injury caused by wound disinfectants.
Journal of Bones and Joint Surgery 1967, 49A : 48-62
2. CIANCI P, BOVE A.
Hyperbaric Oxygen therapy in the treatment of acute and chronic peripheral ischemia.
Internal Medecine 1985, 6 : 117-137
3. GOTTLIEB Sheldon F.
Effect of Hyperbaric Oxygen on microorganisms.
4. HUNT TK, ZEDERFLED TB, GOLDSTICK TK.
Oxygen and healing.
American Journal of Surgery 1969, 118 : 521
5. KINDWALL EP, GLODMANN RW.
Hyperbaric Medecine Procedures.
St Luc's Hospital, Milwarkee 1984:85
6. LAMY M, HANQUET M.
L'oxygénothérapie hyperbare en caisson monoplace à l'oxygène pur.
Laval Medical 1971, 42 : 647-667
7. MONIES-CHASS I, HAGHMONAI M, HOERER D, KAUFMAN TH, STEINER E, SCHRAMEK A.
Hyperbaric oxygen treatment as an adjuvant of reconstructive vascular surgery in trauma.
Injury 1977, 8 : 274-277
8. NYLANDER G, LEWIS D, NORDSTROM H, LARSSON J.
Reduction of postischemic oedema with hyperbaric oxygen.
Presented at the Annual Meeting of the Swedish Society of Plastic Surgeons, April 10, 1984. Gottenburg, Sweden : 596-603
9. SMITH G, STEVENS J, GRIFFITHS JC, LEDINGHAM IM.
Near-avulsion of foot treated by replacement anal subsequent prolonged exposure to oxygen at two atmospheres pressure.
Lancet 1961, 2 : 1122.
10. STRAUSS MB.
Role of hyperbaric oxygen therapy in acute ischemias and crush injuries : an orthopedic perspective.
HBO review 1984, 2 : 87-106
11. SWARTZ W.M., CHA CH., AMBLER M, CLOWES G.
Prolonged ischemia in the replanted rat leg : a biochemical and morphologic study with microvascular techniques.
Surgical Forum Plastic Surgery 1976, 27 : 565