

Hyperbaric Medicine The Past, Present and Future

By: William S. Maxfield, MD, FACNM

The Past:

The first clinical use of hyperbaric oxygen therapy (HBOT), to my knowledge, occurred in the 1890's when it was used to treat infection. It was not until the 1970's, however, that scientific data confirmed the value of HBOT in treating infection. In the 1930's, use of HBOT was promoted by Orville Cunningham, MD with his hotel in Ohio that was a hyperbaric facility. The facility was closed due to opposition by the AMA. Most of the data about HBOT from then until the 1970's derived from treating the bends from diving accidents.

There was also research into administration of radiation therapy while the patient was at pressure from HBOT. This approach caused complications and did not increase survival.

The Present:

When I was on active duty with the navy in the late 1950's, and until the late 1980's, military medicine was the leader in the use of HBOT. I have not found a reason why the value of HBOT for the current injured has been by-passed by military medicine, even for wound healing. The use of HBOT in wound healing, which is the mainstay of civilian HBOT today, increased after the Jessica McClure incident in Texas when her HBOT treatment was recommended by my brother, James R. Maxfield, Jr., MD. Following her significant recovery with HBOT that saved her foot, losing only the tip of her 5th toe, an editorial appeared in the JAMA in which the author of the editorial stated that it was wrong to put Jessica into HBOT. The editorial said animal experimentation would confirm the opinion about the negative effect of HBOT for wound healing. The animal work instead confirmed that HBOT was very beneficial in wound healing and not adverse as had been stated in the JAMA editorial.

Another research project funded to show the lack of value of HBOT was the Bernard Fisher, MD double blind study for MS. When Dr. Fisher's data, instead, showed the value of HBOT for MS, the project was stopped by the MS Society. Today, the MS Society remains negative about HBOT. Use of HBOT for MS is still not an approved indication for MS in the USA. This stance by the MS Society continues in spite of the positive reports on use of HBOT by Richard A. Neubauer, MD. My own experience and data from England on the value of HBOT for MS also corroborates Dr. Neubauer's position. The work of Perrins and James, which reported the 10 year follow up of MS patients who received HBOT vs. controls, again confirmed the value of HBOT for treating MS.

Today, data shows that micro air embolization occurs with traumatic brain injury from blast. This fact, therefore, would explain the progression of the patient's CNS symptoms when evacuated by air from war zones. Remember the rule for diving, "Don't fly for 24 hours post-

deep dive.” Recognition that blast causes micro air embolization, in my opinion, should make blast injury an indication for HBOT just as is the bends.

Other neurological indications for HBOT that are well documented include: treatment of stroke, traumatic brain injury, cerebral palsy, autism, Lyme disease, cortical blindness, and cognitive defects from chemotherapy and surgery. In addition, mitochondrial C disease and ataxia-telangiectasia have responded to HBOT. Diseases that, in my experience, also respond well to HBOT are asthma, emphysema, rheumatoid arthritis, colitis, infected and migrating prosthesis, and reflex sympathetic dystrophy. Complications of radiation therapy and chemotherapy also have had significant response with HBOT as an adjunct to radiation therapy. In 1999, Koshigi et al from Japan reported a significant improvement in brain tumors by using HBOT within 17 minutes before radiation therapy which increased 5 year survival by 50%. This data confirmed my unpublished work with HBOT. Given immediately before each radiation therapy treatment. HBOT achieved a 20-plus year survival for a chest wall synovial sarcoma patient.

The Future:

Additional current research data with HBOT in cancer care, in my opinion, will be the basis for the future expansion of HBOT indications in cancer treatment. This concept is supported by the 2007 data from Norway, which showed in an animal breast cancer model, HBOT was two times as effective as 5FU. Also, in an animal brain glioma model, HBOT produced a 60% reduction in the glioma. This data opens the possibility for use of HBOT as a significant adjunct in future cancer treatment to improve response and survival. This current animal data along with the older reports that show decreased implantability of cancer cells with HBOT, in my opinion, suggests that HBOT should be evaluated before and after invasive procedure treatment to decrease implantability of cancer cells.

In the past, cerebral edema was an approved indication for HBOT based on the animal and human data published by Michael Sukoff, MD. In my opinion, due to politically motivated maneuvers, cerebral edema was removed from the approved indication list. This removal of cerebral edema occurred just as CT and MRI technology provided the ability to measure cerebral edema non-invasively. The developing PET technology for measurement of hypoxia should stimulate the use of HBOT for both CNS pathology and further demonstrate the need for HBOT in cancer care. Remember, the data reported by Sukoff on the value for HBOT in treatment of cerebral edema and hypoxia used invasive measurements.

Meleney ulcer was also removed from the approved list. Now, however, extremity diabetic ulcers are an approved indication. The recent approval of extremity diabetic ulcer confirms the thesis in my 2000 publication of *Why the Diabetic Should Know about Hyperbaric Medicine*.

My concept of where we need to be when HBOT is no longer the best kept medical secret is illustrated in my diagram of the importance of HBOT in modern medicine. Although the USA is considered to be the leader in medicine, there are only 16 indications for HBOT in the USA while in Russia there are 73. Documentation of some of the Russian indications can be seen in

the practice of equine HBOT centers. For instance, the value of HBOT in racehorse mares having a good foal after several failures confirms the Russian indication for use of HBOT in chronic abortion. Also pneumocystis carinii (PC), a common pneumonia in horses, has responded well to the addition of HBOT in the treatment for PC. This data suggests that HBOT should also be considered for patients with AIDS especially in view of the old and new information about the potential for using HBOT in cancer treatment.

Another area in the future where there will be expanded use of HBOT is in the developing field of stem cell therapy. It is now known that a course of HBOT produces an 8 times increase in the patient's stem cell population. The stem cell increase, in my opinion, is the reason for the rapid healing achieved with HBOT. Also this increase in stem cells may contribute to the reported benefit of HBOT and stem cell therapy in spinal cord injury patients who, in other countries, are reported to be walking after paraplegia. From the stem cell conferences I have attended, a major problem has been the low take of implanted stem cells. My belief is that HBOT will increase the take of stem cells, which with the developing technology to image stem cells, will provide a mechanism in the future for documenting the effect of HBOT on stem cell take.

Conclusion:

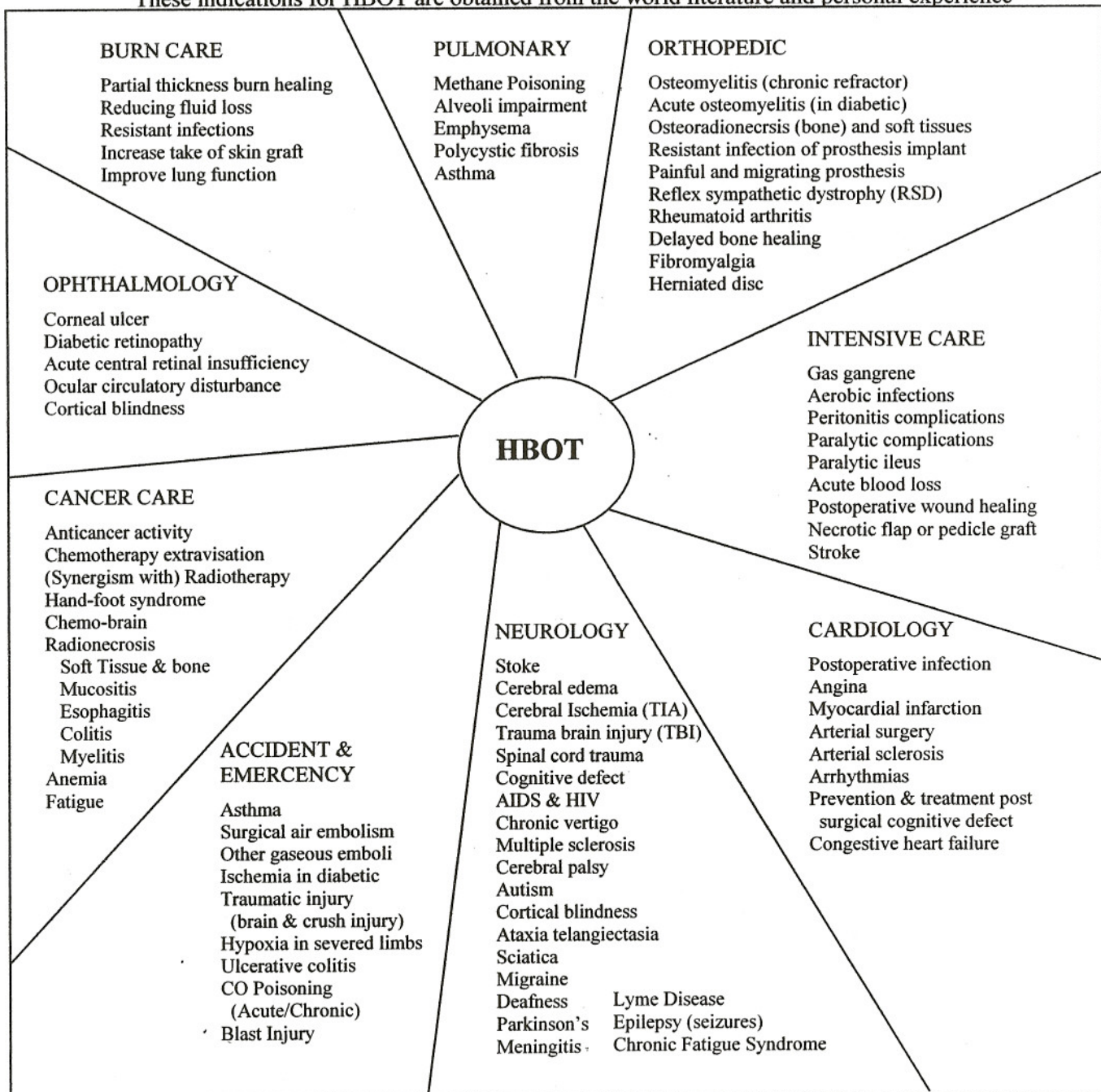
In my opinion, HBOT has application in almost all segments of modern medicine. As HBOT moves from the "best kept medical secret" to usual and customary therapy, there will be significant patient benefit and decreased medical costs. Saving a leg from amputation with HBOT may total \$30,000-\$40,000, but the cost of amputation is \$90,000 plus a 90% chance for loss of the other extremity in five years. Also, consider cost saving by treating patients with cognitive defect from chemotherapy or surgery with HBOT in order to decrease their disability. What we must do now is to move HBOT to the forefront of modern medicine.

Updated Table Presented THE AWAKENING
 Hyperbaric Medical Symposium, San Jose, California, August 27, 2005

Revised for Hyperbaric Oxygen Therapy and the Recoverable Brain 8th International Symposium, July 23-28, 2008
 The Importance of Hyperbaric Oxygen Therapy (HBOT) In Modern Medicine

William S. Maxfield, M.D., FACNM
 P.O. Box 162, Odessa, Florida 33556
wsm@williamsmaxfieldmd.com

These indications for HBOT are obtained from the world literature and personal experience



NOTE: Stem cell therapy may impact all segments of medical care. There is every reason to believe HBOT as supportive therapy for stem cell treatment will be as beneficial as HBOT has been in improving the results of skin and pedicle grafts, especially since data now shows that HBOT increases the stem cell population of the body by a factor of eight.

William S. Maxfield, MD, FACNM

Dr. Maxfield is board certified in radiology and nuclear medicine and was a co-founder in 1988 of the American Board of Hyperbaric Medicine. After many years of clinical and academic practice in radiology, nuclear medicine, and hyperbaric medicine, he is active as a locum tenens radiologist and as a consultant for several hyperbaric medicine programs.

His first contact with Richard A. Neubauer, MD was in 1972 when he brought his father-in-law to Ocean Medical Center for HBOT. Through the ensuing years, Dr. Maxfield worked with Dr. Neubauer and read Ocean Medical Center's SPECT brain scans for many years. He was introduced to hyperbaric medicine while he was on active duty with the U.S. Navy in the late 1950s as a member of the Navy plutonium decontamination team. In 1965, as chief of radiation therapy at Ochsner Foundation Hospital, he incorporated hyperbaric oxygen therapy into design of the new radiation therapy center. His experience in hyperbaric medicine has covered all areas of HBOT including wound healing, neurological indications, orthopedics, and as an adjunct for cancer treatment. Publications in HBOT include his experience with HBOT for MS, treatment of ataxia-telangiectasia, cerebral palsy, care of diabetic patients, and numerous abstracts and scientific exhibits on HBOT in cancer care. Dr. Maxfield's vision for the future of hyperbaric medicine is an increasing role for HBOT in neurology and cancer management. He also foresees an important role for HBOT in stem cell therapy.